

ISSN 0975-7333

Vol. 3 • No. 1

2016



The Journal of Orthopaedics

An Official Publication of Chhattisgarh Chapter of IOA

THE JOURNAL OF ORTHOPAEDICS

AN OFFICIAL PUBLICATION OF THE
CHHATTISGARH CHAPTER OF
INDIAN ORTHOPAEDIC ASSOCIATION

Vol. 3, No. 1, 2016

THE JOURNAL OF ORTHOPAEDICS

An Official Publication of the Chhattisgarh Chapter of IOA
Vol 3, No. 1, 2016

- **Editor :**
Prof. Dr. Alok C. Agrawal
MS Ortho., DNB Ortho, Ph.D. Ortho, MAMS
Head of the Department of Orthopaedics
All India Institute of Medical Sciences, Raipur (C.G.) - 492 099

- **Editorial Advisory Board :**
Prof. K. Sudarshan, Raipur, Prof. R.S. Dhir, Bilaspur
Prof. S.K. Mukherjee, Raipur

- **Member Editorial Board :**
Dr. Vinit Jain, Raipur, Dr. Jayesh Dave, Durg
Dr. Jyotirmay Roychoudhary, Raipur, Dr. M. Rajshekhar, Raipur
Dr. Praveen Jain, Durg, Dr. Purnenedu Saxena, Raipur

- **Editorial Office :**
Dept. of Orthopaedics, All India Institute of Medical Sciences, Raipur (C.G.)
Ph. : 0771-2970149 Mo. : 094251 51634 e-mail : dralokcagrawal@yahoo.co.in

- **Printed by :**
Simplex Printing Press, Jabalpur

- **Composed by :**
Marble Computer, Jabalpur

Copyright in the material contained in this journal (save for advtg. and save as otherwise indicated) is held by the C.G. Chapter of IOA. All rights reserved. The editorial opinions expressed in this publication are those of individual authors and not necessarily those of the publisher. Whilst every effort has been made to ensure the accuracy of the information in this publication, the publisher accepts no responsibility for errors or omissions.

Scientific material for publication should be submitted as for all indexed journals with authors declaration of the material being original/unpublished and not under consideration by any other journal. A conflict of interest statement signed by all authors should be posted at the editorial address.

**INDIAN ORTHOPAEDIC ASSOCIATION
CHHATTISGARH CHAPTER
2016-17**

OFFICE BEARERS

President

Dr. Prakash Bhalerao
Basantpur Road Indrapuri
Rajnandgaon (C.G.)
Mo. : 083492 66869, 094255 74228
E-mail : prakashbhalerao@gmail.com

●
Secretary

Dr. Rajendra Sahu
Sahu Hospital, T.P. Nagar
Korba (C.G.)
Mo. : 098271 77900
Ph. : 07759-245744 / 246744
e-mail : rajendrasahukorba81@gmail.com

●
Patron

Dr. R.S. Dhir
Dr. Subir Kumar Mukherjee
Dr. K.D. Tiwari
Dr. P.L. Chandrakar

●
President Elect

Dr. K.S. Bajpai
Baloda Bazar

●
Immediate Past President

Dr. Akhilesh Kumar Yadav
Bhilai

●
Vice President

Dr. Rajesh Dulhani
Rajnandgaon
Dr. Sanjay K. Prasad
Jagdalpur

●
Joint Secretary

Dr. Deepak Verma
Dr. Rajesh Tembhornikar
Raipur

●
Treasurer

Dr. Vipin Jain
Durg

Editor

Dr. Alok C. Agrawal
HOD, Orthopaedics, AIIMS Raipur (C.G.)
Mo. : 094251 51634
e-mail : dralokcagrwal@yahoo.co.in

●
Clinical Secretary

Dr. Atin Kundu
Jagdalpur
Dr. S. Nath
Korba

●
Executive Members

Dr. Hemant Chatterjee
Dr. Anupam Lal
Dr. Bodh Ram Patel
Dr. Ajay Jaiswal
Dr. V.K. Shukla
Dr. Jayesh Dave
Dr. Sunil Khemka
Dr. B.L. Chandrakar
Dr. S. Chandani
Dr. Susheel Kumar Sharma
Dr. S. Phuljhale
Dr. B.S. Sengar

●
Construction & Protocol Committee

Dr. Ramesh Thawait
Dr. Arun Madharia
Dr. N.C. Khothari

●
Medical Officer Welfare Committee

Dr. Swami Dev
Dr. Rajesh Sadani
Dr. Kedar Agrawal

●
Disability

Dr. Surjeet Singh
Dr. Baghel

●
All Past President are Patrons & Ex. Officio

THE JOURNAL OF ORTHOPAEDICS
VOL. 3, NO. 1, 2016

CONTENTS

		Page
	EDITORIAL : Occupational Burnout of an Orthopaedic Surgeon	A.C. Agrawal 5
1.	Clinical Evaluation of Arthroscopic ACL reconstruction using Quadrupled Hamstring Graft	Ahire R.K., Phuljhe S., Rawte S. 8
2.	Dermatofibrosarcoma Protuberans in the Extremities : Correlation of FNAC with Post-Operative Histopathology in 10 Patients	Kundu P.R., Amritta Kaur S., Kundu Z.S. 15
3.	Fine Needle Aspiration Cytology of Tumors and Tumor-Like Lesions of the Soft Tissues : Its Efficacy	Kundu P.R., Kalra R. Dipti, Kundu Z.S. 19
4.	Bilateral Ilioumbar Ligaments' Ossification in Ankylosing Spondylitis	Nath S. 24
5.	Foreign Body Grannuloma Causing Chronic Osteomyelitis of the Metatarsal – A Case Report	Agrawal A.C., Sahu C., Sahoo B., Jain A. 27
6.	Role of Augmentative Nailing in PerImplant Fracture in a Failed Supracondylar Fracture Femur – A Case Report	Sarangi J., Mohapatra N.C. 30
7.	Clinical, Functional and Radiological Outcome Following Herbert Screw Fixation of Capitellum Fracture	Bhatia C., Goel N., Goel R., Thalanki S. 33
8.	Hereditary Multiple Exostosis : A Case Report	Verma S., Deshwar G., Sharma B., Pal C.P. 38
9.	A Comparative Study of Different Treatment Modalities of Lumbar Canal Stenosis	Pal C.P., Srivastav D.C., Singh P., Dinkar K.S. 41 Mittal V., Deshwar G.
10.	Femoral Fractures in Children : Early Fixation with Elastic Nail	Garg I.K., Jain G., Singh A., Kumar L. 45
11.	A Rare Presentation of Giant Cell Tumor Involving the Proximal Phalanx of Great Toe – A Case Report	Pradhan C.S., Mohapatra N.C., Rana R. 49 Das B.
12.	Evaluation of Outcome of Intertrochantric Femoral Fractures Treated with Proximal Femoral Nail in 200 Patients	Sharma N., Agrawal A., Bhargava R. 52 Singh S.P., Singh V., Krishna V.

OCCUPATIONAL BURNOUT OF AN ORTHOPAEDIC SURGEON

Agrawal A.C.

Keywords: burnout; emotional exhaustion; depersonalization; burnout prevention; burnout treatment

The term Occupational Burnout has been used since the early 1970s, when the effects of emotional stress on behavior and professionalism among caregivers and human services workers were considered important.^{1,2,3,4}

Occupational burnout syndrome consists of:

1. Emotional exhaustion
2. Depersonalization (ie, a detached, cynical view of patients and colleagues), and
3. A perceived lack of personal accomplishment.^{1,2}

In a USA based study of 7,288 physicians, Shanafelt et al⁵ found that physicians experienced a significantly higher incidence of burnout symptoms than did workers from the general population (37.9% versus 27.8%). He also noted that 45.8% of physicians reported at least one symptom of burnout. It was found that nearly half of orthopaedic surgeons experienced symptoms of burnout-outnumbered only by the physicians in emergency medicine, general internal medicine, and family medicine subspecialties. This finding is consistent with several studies in the orthopaedic literature that have examined burnout symptoms in practicing surgeons, academic leaders, and trainees around the world.⁶⁻⁹ These studies have reported burnout rates of 40% to 60%.¹⁰⁻¹²

Several studies have noted that surgeons, faculty leaders, and trainees suffer different types of burnout at various rates; therefore, those roles must be investigated independently^{7,12}). Among practicing surgeons and faculty members, burnout is marked by high levels of emotional exhaustion and depersonalization, whereas feelings of personal achievement are often preserved. This pattern is consistent in several studies in the literature.^{10,11,12} Orthopaedic faculty leaders, such as Head of the Departments, also exhibit this pattern of burnout, but they experience higher rates of emotional exhaustion. Salehet al¹¹ found that 38% of orthopaedic department chairs scored in the highest range of emotional exhaustion, and Sargent et al¹² reported high levels of burnout in 28% of orthopaedic faculty. In an earlier study of 195 academic orthopaedic department leaders, Saleh et al¹¹ found that residency program

directors suffered the highest rates of exhaustion, with 52% of respondents scoring in the highest range.

Sargent et al⁷ analyzed burnout rates in orthopaedic faculty and found that the rates vary depending on surgeon and program status. Young academic surgeons practicing <10 years reported notably higher rates of emotional exhaustion and depersonalization than did those who had been practicing longer. It is likely that older surgeons have broader perspectives and superior coping mechanisms. Sargent et al⁷ hypothesized that attrition in the field may play a role, as well. The authors found that faculty who work in larger programs are more likely to display symptoms of loneliness and increased irritability, which may reflect increased stress in high-volume tertiary referral centers. In contrast to practicing surgeons, faculty, and faculty leaders, orthopaedic trainees report high levels of emotional exhaustion, very high levels of depersonalization, and feelings of low personal accomplishment.

Using the Maslach Burnout Inventory (MBI), the 12-Item General Health Questionnaire, and the Revised Dyadic Adjustment Scale, Sargent et al⁷ surveyed 384 US orthopaedic trainees and 264 faculty members and found that 56% of residents scored at the highest level of detachment compared with only 24.8% of faculty.

EFFECTS OF BURNOUT

Burnout can result in negative outcomes for surgeons and trainees. The symptoms alone reduce quality of life; emotional exhaustion is associated with physical exhaustion and poor judgment, depersonalization results in cynicism and impaired relationships with patients and colleagues, and feelings of low personal achievement lead to decreased effectiveness and productivity.¹¹ The syndrome can also lead to depression,⁴ alcohol and drug abuse,¹³ and physical illness, such as male infertility, diabetes mellitus, and heart disease.¹² Burnout has been associated with increased risk of metabolic syndrome, dysregulation of the sympathetic nervous system and the hypothalamic-pituitary-adrenal axis, and myocardial infarction.^{14,15}

Surgeon burnout can have negative effects on

personal and institutional levels, potentially resulting in a negative attitude, poor performance, absenteeism, and increased employee turnover.¹⁹ It can also lead to medical errors.

RISK FACTORS

Rigorous work is needed to maintain a professional orthopaedic surgical practice and gain financial and job security. Burnout should be considered when surgeons experience difficulty in relationships with colleagues, staff, or family members. The common cited risk factors and methods to identify are as follows:

1. Rigorous work
2. Emotional exhaustion with anxiety regarding clinical competence, concern about the growing number of orthopaedic surgeons, difficult relationships with other faculty members, financial concerns, increased stress at work, and increased conflict between work and home life.¹⁶
3. Among residents, emotional exhaustion may be associated with anxiety regarding clinical competence, stressful relationships with senior residents and faculty, increased stress at work, and increased conflict between life at work and at home.
4. Depersonalization in faculty members was associated with a greater number of work hours, increased alcohol use, and stress in relationships with nursing staff.
5. Depersonalization in residents was associated with longer work hours, increase in anticipated debt, and stress in relationships with nursing staff.
6. For both faculty and residents, perceived personal achievement scores correlated with quality of life at home, including marriage and parenthood.¹⁶

DIAGNOSIS

The MBI-HSS, a 22-question validated instrument, facilitates an objective diagnosis of burnout. Three domains of burnout are assessed: emotional exhaustion, depersonalization, and sense of personal accomplishment.¹

TREATMENT

Treatment and prevention of burnout continue to present a considerable challenge to the medical community. Minimal evidence-based literature has described effective interventions to treat the condition. However, several recent studies provide a starting point for treatment of persons affected by burnout and

prevention at the institutional level. Mindfulness based interventions and counselling sessions should include physical and emotional self awareness, education and hath yoga. Stress management and coping education should include counselling.

PREVENTION

In addition to individualized treatment, prevention is crucial to limiting the effects of burnout on surgeons and institutions. Optimizing protective factors at both the individual and institutional/residency program levels may help reduce the prevalence of burnout. For faculty, decreased burnout was correlated with increased perception of a supportive work environment, the presence of a mentor, acceptance into a national specialty organization, and the absence of personal issues in the workplace.

Meditation, making time for exercise/hobbies, limiting alcohol use, and spending quality time with a spouse also decreased burnout.¹²

For residents, several factors were found to be protective, including perceived support from other medical institutions, working with an in-program mentor, leaving personal concerns outside work, personal time focused on exercise and hobbies, taking vacations, limiting alcohol use, and drawing on religion or faith.¹²

In another study by Sargent et al,¹⁶ the authors found that an increase in hours worked by spouses correlated with an increase in perceived personal achievement scores. The second control group showed that residents with a parent who is a physician correlated with reduced emotional exhaustion and depersonalization.

In their study of burnout in orthopaedic chairpersons, Salehet al⁷ also found that strong personal relationships, most notably relationships with spouses or children, were among the most powerful protective factors against emotional exhaustion. Establishing effective time and energy management skills or attending stress and marriage workshops can strengthen marital and family bonds. The authors recommended that orthopaedic surgeons use strategies for stress management and performance that work with, not against, autonomic nervous system responses. Compared with avoidance strategies, these preventative measures are similar to the coping mechanisms used by elite athletes. Athletes are taught to handle unmet performance expectations and other stressors by responding proactively and demonstrating problem-solving skills.¹³

To minimize burnout, Choong¹⁷ recommends that

institutions ensure that the expectations of both the practicing surgeon and institution be understood and mutually agreed on at the outset. Institutions should also optimize infrastructure and support for surgeons, outline a system of rewards for surgeon contributions, clarify guidelines for promotion, and create mentorship opportunities for younger surgeons. Critical elements that reduce burnout include increasing physician autonomy, work efficiency, and satisfaction; encouraging participation in leadership opportunities; improving fairness; and streamlining workflow.¹⁷

Indian medical association suggests the following remedies to cope up with burnout syndrome:

- In distress, open the eyes of your mind and ask yourself the options.
- When faced with multiple options, open the eyes of your heart, and choose the one, which gives you comfort i.e. a conscience-based decision.
- Follow Buddha's principle of right speech: Before you speak, ask yourself: Is it the truth? Is it necessary? Is it kind? If the answer to any is 'no', do not speak.
- Follow Buddha's principle of right action: Before doing any action ask yourself: Is it the truth? Is it necessary? Will it bring happiness to me? Will it bring happiness to others? If the answer to any is 'no', do not do that action.
- You can also choose three different ways: Think of an opposite solution, think of a different solution or think of a positive solution.
- Stress is the acute or chronic reaction of the body and/or the mind to the interpretation of a known situation. So either change the situation, or make it not known to you, or practice a lifestyle in a way that stress does not react on you.
- Do not get upset. Remember that even in people growing in higher states of consciousness, the experience of anger can be frequently triggered by minor incidents
- Practice STOP principle.
 - S: Stop
 - T: Take a deep breath and smile
 - O: Observe how you feel
 - P: Proceed with awareness

The best solution is to practice chanting of "UUUUMMMM" with a speed of 4-5 per minute (slower and deeper parasympathetic breathing).

REFERENCES

1. Maslach C, Jackson SE, Leiter M: Maslach Burnout Inventory Manual, ed 3. Palo Alto, CA, Consulting Psychologists Press, 1996.
2. Maslach C, Schaufeli WB, Leiter MP: Job burnout. *Annu Rev Psychol* 2001;52:397-422
3. Shanafelt TD, Balch CM, Bechamps GJ, et al.: Burnout and career satisfaction among American surgeons. *Ann Surg* 2009;250(3):463-471
4. Vijendren A, Yung M, Sanchez J: The ill surgeon: A review of common work-related health problems amongst UK surgeons. *Langenbecks Arch Surg* 2014;399(8):967-979
5. Shanafelt TD, Boone S, Tan L, et al.: Burnout and satisfaction with work-life balance among US physicians relative to the general US population. *Arch Intern Med* 2012;172(18):1377-1385
6. Arora M, Diwan AD, Harris IA: Burnout in orthopaedic surgeons: A review. *ANZ J Surg* 2013;83(7-8):512-515
7. Sargent MC, Sotile W, Sotile MO, Rubash H, Barrack RL: Quality of life during orthopaedic training and academic practice: Part 1. Orthopaedic surgery residents and faculty. *J Bone Joint Surg Am* 2009;91(10):2395-2405
8. Saleh KJ, Quick JC, Sime WE, Novicoff WM, Einhorn TA: Recognizing and preventing burnout among orthopaedic leaders. *ClinOrthopRelat Res* 2009;467(2):558-565
9. Lesic AR, Stefanovic NP, Perunicic I, Milenkovic P, Tosevski DL, Bumbasirevic MZ: Burnout in Belgrade orthopaedic surgeons and general practitioners: A preliminary report. *ActaChirIugosl* 2009;56(2):53-59
10. VanVendeloo SN, Brand PL, Verheyen CC: Burnout and quality of life among orthopaedic trainees in a modern educational programme: Importance of the learning climate. *Bone Joint J* 2014;96-B(8):1133-1138
11. Saleh KJ, Quick JC, Conaway M, et al.: The prevalence and severity of burnout among academic orthopaedic departmental leaders. *J Bone Joint Surg Am* 2007;89(4):896-903
12. Sadat-Ali M, Al-Habdan IM, Al-Dakheel DA, Shriyan D: Are orthopedic surgeons prone to burnout? *Saudi Med J* 2005;26(8):1180-1182
13. Campbell DA Jr, Sonnad SS, Eckhauser FE, Campbell KK, Greenfield LJ: Burnout among American surgeons. *Surgery* 2001;130(4):696-705
14. Toker S, Melamed S, Berliner S, Zeltser D, Shapira I: Burnout and risk of coronary heart disease: A prospective study of 8838 employees. *Psychosom Med* 2012;74(8):840-847
15. Melamed S, Shirom A, Toker S, Berliner S, Shapira I: Burnout and risk of cardiovascular disease: Evidence, possible causal paths, and promising research directions. *Psychol Bull* 2006;132(3):327-353
16. Sargent MC, Sotile W, Sotile MO, Rubash H, Barrack RL: Stress and coping among orthopaedic surgery residents and faculty. *J Bone Joint Surg Am* 2004;86(7):1579-1586
17. Choong PF: Burnout: A leadership challenge. *ANZ J Surg* 2013;83(7-8):495-496
18. Agrawal SS, Aggrawal KK: Dentist beaten to death. *eMedinews* 27-03-2016

CLINICAL EVALUATION OF ARTHROSCOPIC ACL RECONSTRUCTION USING QUADRUPLED HAMSTRING GRAFT

Ahire R.K.*

Phuljhele S.**

Rawte S.***

ABSTRACT

In a prospective study on ACL reconstruction we treated 22 patients with autogenous quadrupled hamstring (doubled semitendinosus/doubled gracilis) in an ACL deficient knee. The range of follow up was 6 months to 2 years with mean duration of 1.6 years. Most of the patients in our series 63.6% cases were in the age group of 25-34 years. In our series isolated ACL tear was found in 36.3% cases, associated medial meniscus tear in 31.8%, lateral meniscus in 22.7% cases while associated both meniscus tear in 9% cases. After ACL reconstruction, most of the patient (81.8%) in our series regained good range of motion (0-120 and above). Overall results assessed by Lysholm knee score were excellent in 36.3%, good in 45.5%, fair in 13.6% and poor in 4.5%. No major complication was seen except superficial infection in 3 cases (13.6%). **CONCLUSION:** Arthroscopic ACL Reconstruction Using Quadrupled Hamstring Graft is a safe and good option in the treatment of athlete and high demanding patients who has to undergo pivoting most often in their life time. It is a reliable method for anterior cruciate reconstruction for chronic cruciate ligament insufficiency.

INTRODUCTION

The knee joint is frequently involved in sports injuries and as modern sport is being more and more competitive, more complex knee injury patterns are being recognized. Anterior cruciate ligament is a very commonly involved ligament in these injuries. More and more cases of ACL tear are being diagnosed nowadays due to the increasing role of MRI as a diagnostic tool. Anterior cruciate ligament is one of the most important intra-articular ligaments of the knee joint. It is an intra-articular, extrasynovial structure present in the central complex of knee joint. It functions in concert with all other anatomical structures in the knee joint to control and limit motion and to maintain both static and dynamic equilibrium. It is attached proximally to the posterior part of the intercondylar surface of the lateral femoral condyle and distally just antenolateral to the anterior tibial spine. ACL injury commonly occurs in football, volleyball, basketball, skiing etc and is usually caused by deceleration, twisting, cutting and jumping maneuvers or by hyperextension of the knee. In traditional Indian sport like Kabbadi, playing Kho-Kho, rural wrestling pivoting is more common. Even day to day activities patient can sustain ACL injuries like stepping down from bus, fall from stairs etc. The goal of the surgical treatment is to

restore knee stability, thus preventing recurrent knee injury while allowing the patient to return to his preinjury activity levels and sports. Young patients who are unwilling to modify their active lifestyle and who have further interest in sports should be considered for surgical intervention. Obtaining the normal range of motion and regaining strength equal to uninjured leg are important. The application of knee arthroscopy to patient care has steadily expanded over the past two decades. Arthroscopically assisted techniques for ACL reconstruction have resulted in smaller incisions without disturbing adjacent uninvolved anatomic structures. The recovery and rehabilitation following these procedures has also been shortened. Various surgical procedures and graft selections have been proposed for ACL reconstruction such as bone-tendon-bone (BTB), semitendinosus tendon (ST), iliotibial band, allograft, and quadriceps tendon. Among these the central third of patellar tendon and hamstring tendons have been the most common type of graft used. Bony fixation and mechanical strength may explain the success of the patellar tendon graft, whereas the use of a four - bundle semitendinosus- gracilis graft guarantees high graft strength and a clinical outcome similar to that found in BPTB graft. Various mode of fixation are also available like transfixation device, endobutton, bioscrews, ligament

* Asso. Prof.
** Professor
*** Resident

Address for correspondence:
Dr. R.K. Ahire
Asso. Prof.
Department of Orthopaedics
Pt. J.N.M. Medical College
Raipur (C.G.)

staples etc. Present study aims to evaluate the results of Anatomical reconstruction of ACL using autogenous quadrupled Hamstring graft.

MATERIAL AND METHODS

This study is conducted in the department of Orthopaedics among the patients attended OPD and Casualty of PT.J.N.M.MEDICAL COLLEGE and associated DR B.R. AMBEDKAR MEMORIAL HOSPITAL, RAIPUR (C.G.).

Inclusion Criteria: a) Patient having symptomatic Anterior Posterior instability of knee joint. b) Clinically having positive Lachmann and Anterior Drawer test. c) ACL deficient knee diagnosed in MRI. d) Such patient willing and medically fit to undergo arthroscopic procedure.

Exclusion Criteria: a) Patient with compounding injury and fracture of periarticular structure of knee joint. b) Any local infection. c) Ankylosed knee joint. d) Local skin infection around potential portal site. e) Thrombophlebitis. f) Any bleeding diathesis disorder. Preoperative evaluation is done by taking detail history, clinical examination of knee joint for effusion, wasting of quadriceps muscle, tenderness, range of movement, lachman test, Anterior-posterior drawer, test, Varus-Valgus stress test, McMurray test, and Pivot shift testis done. Pre operative Lysholm knee scoring is done. X-ray of knee joint Antero-posterior (standing) and lateral view with MRI of knee joint is taken. Complete haematological investigation is done. Pre-Anaesthetic check up is taken. All patients were undergone compulsory Physiotherapy for strengthening of Hamstring, Quadriceps and Vastus medialis Obliquus muscles as well as range of movement of knee joint for 4 weeks before surgery.

SURGICAL PROCEDURE

All cases were done in Regional Anaesthesia (Spinal block) and under pneumatic tourniquet control. Supine position was given. In all cases femoral tunnel fixation is done with Endo button (Endocl-smith and nephew) and tibial tunnel by interference screw (titanium). Diagnostic Arthroscopic was done in all cases to confirm the injury. Hamstring tendon (Semitendinosus and Gracilis) was harvested from the same side with the help of tendon stripper. After harvesting, the graft was placed on graft master board. They were stripped of their residual muscle fibers proximally using the blunt end of scalpel blade. The tendon end were carefully trimmed to uniform size and measured and made of equal lengths. Both tendons are laced together using number-5 Ethibond suture a running baseball stitch was placed in both tendons in a Chinese finger trap configuration.

About 3-4 cm of both ends of tendons was stitched together. The tendons were looped (using an umbilical tape around the stitched tendons) and passed through various holes in the graft sizer. The diameter of reamer chosen for subsequently making the tunnels was equivalent to smallest sizing sleeve that passed over the four stranded graft with minimal friction. Circular marks were made equal to the size of femoral tunnel distal to proximal end of the loop for viewing arthroscopically the accurate placement of the graft inside the femoral tunnel. The loop of the quadrupled tendons (doubled semitendinosus and doubled gracilis) was then passes through ENDO-CL of appropriate size. This size is calculated (femoral tunnel + tibial tunnel + 20mm). And then the quadrupled graft was tied with 3-0 absorbable suture up to 2 cm distal towards Endo CL end then tied to the graft master posts and a pressure of about 15 pounds was applied for 10-15 minutes for pre-tensioning the graft.

Tibialtunnel preparation - ACL zig kept 4cm below the joint line, medial to tibial tuberosity and angle was make 55 degree with long axis of tibia 2 cm proximal to pes anserinus and 1.5 cm medial to tibial tuberosity, and drilling was done according to the graft size.

Femoral tunnel preparation - all cases are done through Antero-medial portal with the knee hyperflexed to 110 degrees or more. The guide pin inserted to opposite cortex in femur through AM portal over the footprint. The starting point is at the 10.30 o'clock position on the Rt side 1.30 o'clock position on Lt side. Long k-wire is passed through this entry point and through this K-wire 4mm cannulated drill bit was passed thoroughly. Femoral tunnel length was measured. Then with appropriate size (equivalent to the size of graft) flower drill bit femoral tunnel was made 1-1.5 cm smaller than the actual length of tunnel measure earlier.

Graft is attached with Endocl, two limb tendon grafts fixed with one endobutton. Then with the help of bid pin double loop thread was passed from AM portal to femoral tunnel. This loop was left at intercondylar notch area and with the help of grasper through tibial tunnel thread loop was pulled back from tibial tunnel. Now the pre tensed quadrupled graft with Endo-CL was passed into the loop and thread at its thread point. Now the thread was pulled towards femoral tunnel till the endobutton reaches the entry point and femoral tunnel. Then only one thread either green or white was pulled back through femoral tunnel till a click is felt (endobutton coming out). Now other thread was also pulled. Then flip test was done to confirm that endobutton is out of the lateral femoral cortex. After finding satisfactory flip test the graft was now pulled from another end. The knee was

extended fully followed by passive range of movement of knee joint was performed while tensioning the graft at the same time. Then appropriate size of interference screw (one size larger than tibial tunnel) was tightened in tibial tunnel.

POST-OPERATIVE CARE AND FOLLOW UP

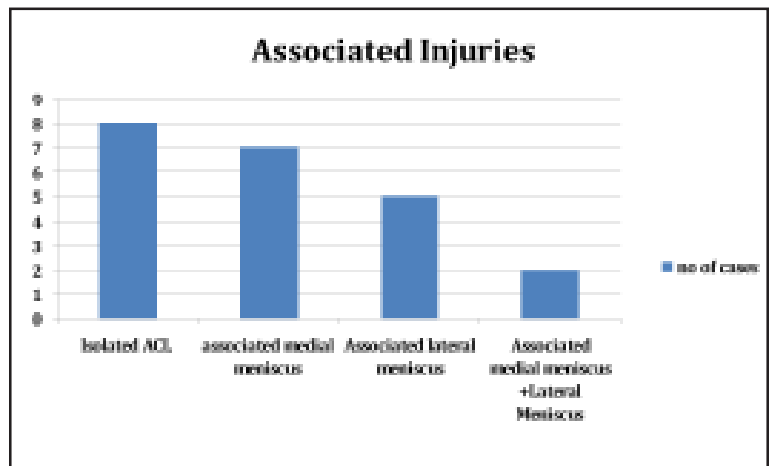
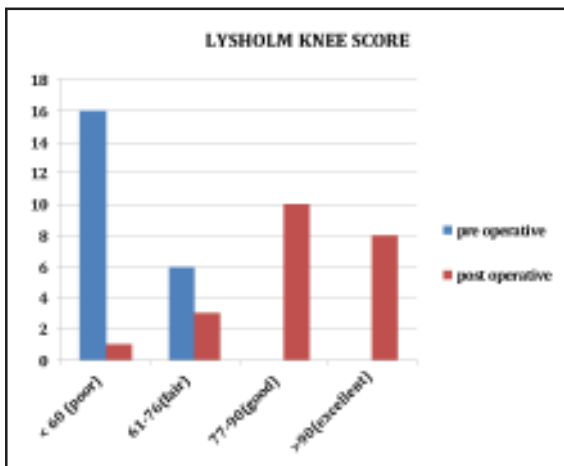
Patients were given intravenous antibiotics for 3 days post-operatively. Wound inspection was done on the 3rd postoperative day and the patient is discharged on oral antibiotics if the wound was good. On the 14th day stitch removal was done.

Active static quadriceps exercises and ankle pumps were started as soon as the patient recovered from anesthesia. Knee range of movement was started on 3-5 post operative day. Post-operatively patient was placed in knee brace for one month. Partial weight bearing with crutches, with 50% of the body weight was allowed for one month. Mobilization was started immediately, giving priority to the recovery of full extension. CPM was also used to help flexion. The crutches are maintained until quadriceps control was reestablished: typically about 4 weeks. Standard ACL reconstruction rehabilitation protocol was then followed. Sports activity was allowed after 3 months. Cutting and pivoting sport activities were started by 6 months. Patients were followed every month for first 6 months followed by every 3 monthly for 1 year; Subsequently 6 monthly postoperatively. In each follow up evaluation was done by Lysholm knee score. The results were graded as per Lysholm knee score-

- <60 = Poor
- 61-76 = Fair
- 77-90 = Good
- >91 = Excellent

RESULTS

Between May 2010 to June 2012, 22 patients with ACL tear were treated arthroscopic reconstruction using autogenous hamstring graft. The range of follow up was 6 month to 2 years with mean duration of 1.6 years. Most of the patients in our series 14 cases (63.6%) were in the age group of 25-34 years followed by 15-24 years age group 7 cases (31.8%). All the patients were male (100%). Out of 22 cases, in 15 cases (68%) right knee joint whereas in 7 cases (31.8%) left knee joint was involved. Sports injuries accounted for 54.5% (12 cases), vehicular accidents 40.9% (9 cases) and in 4.5% (1 patient) case injury occurred while in daily activity (slipped down). In our series isolated ACL tear was found in 8 cases (36.3%), associated medial meniscus tear was in 7 cases (31.8%), associated lateral meniscus in 5 cases (22.7%) while associated both meniscus tear was there in 2 cases (9%). No case was associated with PCL and LCL tear while 1 patient was having partial tear of MCL associated with both meniscus tear. After ACL reconstruction, most of the patient (81.8%) in our series regained good range of motion (0-120 and above), 3 cases (13.6%) had > 15 degree loss of terminal flexion and 1 case (4.5%) had > 5 degree restricted terminal extension. Overall results assessed by Lysholm knee score were excellent in 36.3% (8 cases), good in 45.5% (10 cases), fair in 13.6% (3 cases) and poor in 4.5% (1 case). No major complication was seen in our series except superficial infection in 3 cases (13.6%) and difficulty in regaining motion in knee joint in 1 cases (4.5%). Graft impingement occurred in 1 case which was treated at the same sitting by notchplasty. There was no case of graft avulsion. The average tourniquet time in our series was 90 min and there was no case of tourniquet palsy.



CLINICAL EVALUATION OF ARTHROSCOPIC ACL RECONSTRUCTION USING QUADRUPLED HAMSTRING GRAFT

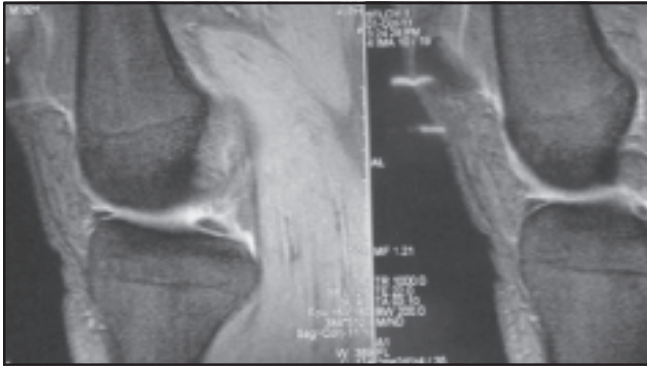

Fig. 1 : MRI shows complete ACL tear

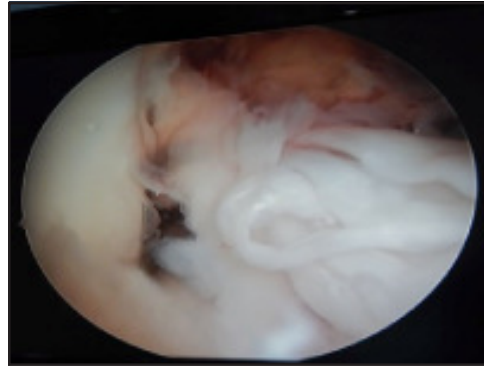


Fig. 2 : Arthroscopic finding of Complete tear of ACL (empty lateral wall sign)

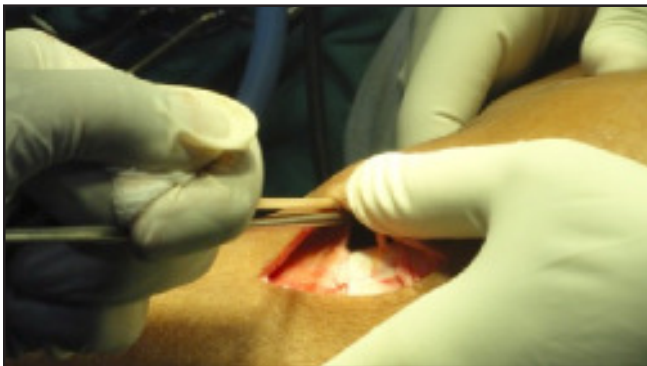

Fig. 3 : Harvesting graft with tendon stripper



Fig. 4 : Pre tensioning of graft in graft board

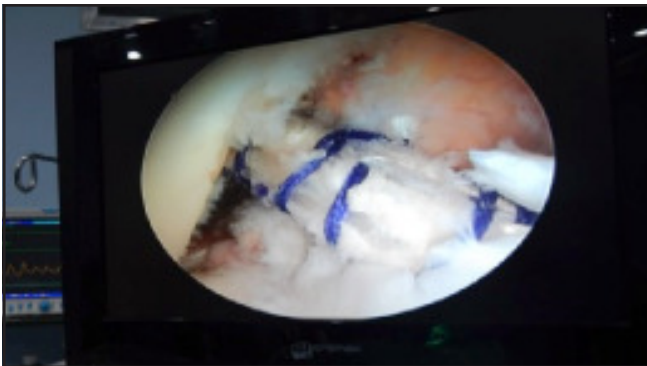


Fig. 5 : Passage of graft through femoral tunnel

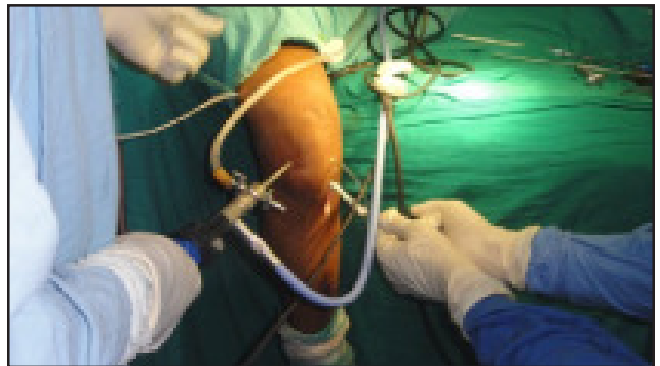

Fig. 6 : Final tensioning of graft

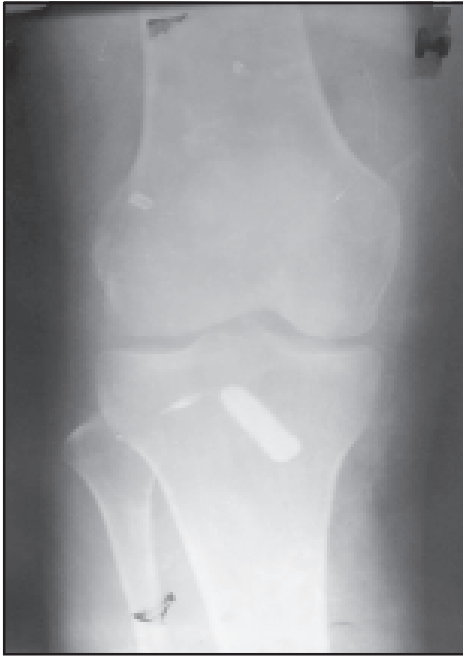

Fig. 7 : Post op X-ray AP view

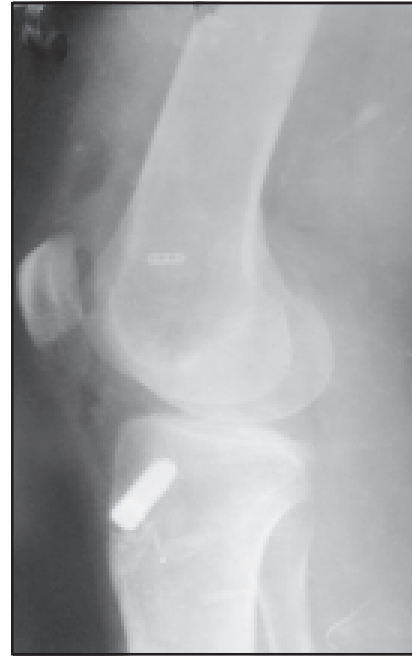

Fig. 8 : Post op X-ray lateral view

DISCUSSION

Anterior cruciate ligament is a common occurrence these days due to increased participation in sports and vehicular accidents. It was controversial whether all patients with anterior cruciate deficient knee require construction of ACL. Daniel DM et al² and R Sandberg et al³ have presented patients with ACL injuries who resumed normal lifestyle without surgical intervention. In contrast to this Johnson et al⁴ reported high incidence of meniscus tears, early traumatic arthritis and functional instability in individuals with ACL deficient knees. There is now little doubt that anterior cruciate ligament deficiency causes progressive deterioration of knee function and stability in due course of time, especially in active individuals. Surgical reconstruction has become the standard of care in the treatment. The primary goal of the reconstruction is to restore the stability to the knee and thereby, presumably to restore its function and allow the patient to return to normal activities, including sports. Another goal is to prevent early degenerative changes.

Most of our patients in our series 14 cases (63.6%) were in the age group 25-34 years, followed by 15-24 years age group 31.8% (7 cases). All cases were male patients. Brig VP Pathania et al⁵ in their study, the maximum number of patients, 10 cases (40%) were grouped between 25-30 years of the age. R.J. Johnson et al⁴ in their series the mean age was 26.3 years and

median age was 25.0 years. The study included 23 (92%) males and 2 (8%) females. In our series 68% of the cases, right knee was involved. The ratio of the right knee to left knee in this series was 2.1:1. Brig VP Pathania, et al.⁵ in their series 60% of the cases right knee was involved. R.J. Johnson et al⁴ in their study, right to left knee involvement ratio was 1.2:1. Sports injuries 54.5% (12 cases) and vehicular accidents 9 cases (40.9%) predominates as mode of injury in our series, other injuries (daily activities) comprises of only 4.5% (1 case) who sustain injury while stepping down from stairs. Amongst sports injuries football was the leading sports involved followed by cricket. William G Clancy et al⁶ found in 88% of their cases the mode of injury was sports especially football. In this study a total of 14 patients (63.6%) cases who had some associated injuries along with ACL tear. There were 12 cases (54.5%) associated with meniscal injury. Isolated medial meniscus tear were found in 31.8% (7 cases) while isolated lateral meniscus tear were present in 22.7% (5 cases) of the patients. Combined medial and lateral meniscus tears were found in 2 cases (9%). All patients of meniscus injury were treated by partial menisectomy in the same sitting. Kruger- Franke M et al⁷ in their series of 107 patients found that 55% of the acute ACL ruptures involved a tear of the lateral meniscus, 45% of the medial meniscus, and 34% had a lesion of medial collateral ligament. In their series the most frequent combination of

the injuries with ACL rupture was the tear in both menisci and the lesion of the medial collateral ligament with the tear in the lateral meniscus. Meniscus injury may occur at the time of initial injury along with ACL tear or later on in a chronic cruciate ligament deficient knee. In chronic ACL insufficiency meniscus damage occurs more often (60%) as seen in the series of Russel F Warren et al⁸. Indelicato PA et al⁹ in their series found that the incidence of the meniscus tear increased from 77% in the acute injuries to 91% in the chronically re-injured knee: furthermore, articular surface disease increased from 23% in the acute injury to 54% in the chronically ACL lax knee. The majority of the meniscus tear in their series were medial. They concluded Irrespective of how one approaches ACL insufficiency of the knee acutely, one cannot ignore the likelihood of finding these significant associated lesions. Reinjury to the knee will likely enhance the incidence of meniscal tears and articular changes. After ACL reconstruction, most of the patient (81.8%) in our series regained good range of motion (0-120 and above), 3 cases (13.6%) had > 15 degree loss of terminal flexion and 1 case (4.5%) had > 5 degree restricted terminal extension. Brig. V P Pathania et al⁵ in their series had 92% (23 cases) patients had full range of movement. 2 (8%) patients had restriction of last 10° of flexion and 2 (8%) patients had extension deficit of 5°. In JM Webb series¹², at 24 months follow up 99% patients had full flexion or lacked less than 5° and 1% lacked more than 7° of flexion. 97% patients had full extension or lacked < 3° and 3% were lacking 4°-5° of full extension. In KD Plancher et al¹³ series, the average post-operative knee flexion was 136° (112-150). One knee flexed to less than 125° post-operatively.

Overall results assessed by Lysholm knee score were excellent in 36.3% (8 cases), good in 45.5% (10 cases), fair in 13.6% (3 cases) and poor in 4.5% (1 case). The satisfactory results (excellent + good) were found to be 81.8% (18 cases). Whereas Brig VP Pathania et al⁵ found 16% (4 cases) of cases excellent, 60% (15 cases) good result and fair in 24% (6 cases) in their case series of 25 patients. The overall satisfactory result was found to be 76%.

In this case series there were no major complication seen except superficial infection in 3 cases (13.6%). 1 case (4.5%) had difficulty in regaining the motion. Graft impingement occurred in 1 case (4.5%) was detected after the graft fixation which was treated in same sitting by notchplasty. There were no cases in our series which had graft avulsion. The superficial infection were treated and responded well to intravenous antibiotics. The average tourniquet time in our series was 90 minutes and there were no case of tourniquet palsy in our series. Kazunori Yasuda, et al¹⁰ in their series did not

experience any intraoperative problems concerning tunnel positioning, the graft placement, or the graft fixation. There were no post-operative complication, such as infection, neurovascular injury, cartilage injury, injuries in other knee structures or delayed wound healing. T muneta, H. Koga et al¹¹ in their series found that there was no problematic loss of knee motion in either the single bundle or double bundle group.

SUMMARY

Arthroscopic ACL reconstruction using autogenous quadrupled Hamstring graft aims to reconstruct the torn ligament and is bio-mechanically stable, closely resembling the native ACL; which provides stability & knee kinematics close to anatomic ACL. It is good option in the treatment of athlete and high demanding patients who has to undergo pivoting most often in their life time. It is a reliable method for anterior cruciate reconstruction for chronic cruciate ligament insufficiency. Limitation of this study is small number of patients and shorter period of study. The procedure has the long learning curve and the surgery should be performed by experienced surgeon. More quantitative and long follow up studies are required in future to know long term outcomes of this procedure.

REFERENCES

1. T. Natsu-ume, K. Shino, K. Nakata, N. Nakamura, Y. Toritsuka, T. Mae, Endoscopic reconstruction of the anterior cruciate ligament with quadrupled hamstring tendons A CORRELATION BETWEEN MRI CHANGES AND RESTORED STABILITY OF THE KNEE J Bone Joint Surg [Br] 2001;83-B:834-7.
2. Daniel DM, Stone ML, Dobson BE, Fithian DC, Rossman DJ, Kaufman KR Fate of the ACL-injured patient. A prospective outcome study, Am J Sports Med. 1994 Sep-Oct;22(5):632-44.
3. Sandberg R, Balkfors B, Nilsson B, Westlin N: Operative versus non-operative treatment of recent injuries to the ligaments of the knee. A prospective randomized study, J Bone Joint Surg Am. 1987 Oct;69 (8):1120-6.
4. JOHNSON, R. J; ERIKSSON, E.; HAGGMARK, T; POPE, M. H.: Five-to Ten-year Follow-up Evaluation after Reconstruction of the Anterior Cruciate Ligament, Clin Orthop 1984;183:122-140
5. Brig VP Pathania, VSM, Sqn Ldr Sandeep Gupta+, Lt Col GR Joshi: Anterior Cruciate Ligament Reconstruction with Bone Patellar Tendon Bone Graft through a Mini Arthrotomy, MJAFI, vol 60, no-1, 2014.
6. W G Clancy Jr; D A Nelson; B Reider; R G Narechania: Anterior cruciate ligament reconstruction using one-third of the patellar ligament, augmented by extra-articular tendon transfers. J Bone Joint Surg Am, 1982 Mar; 64 (3): 352 -359

7. Krüger-Franke M1, Reinmuth S, Kugler A, Rosemeyer B: [Concomitant injuries with anterior cruciate ligament rupture. A retrospective study]; Unfallchirurg. 1995 Jun;98 (6):328-32.
8. WARREN, RUSSELL F. M.D.; LEVY, I. MARTIN M.D: Meniscal Lesions Associated with Anterior Cruciate Ligament Injury, Clinical Orthopaedics & Related Research, January/February 1983 - Volume 172 - Issue - ppg 32-37
9. Indelicato PA, Bittar ES: A perspective of lesions associated with ACL insufficiency of the knee. A review of 100 cases. Clin Orthop Relat Res. 1985 Sep; (198):77-80.
10. Kazunori Yasuda, Eiji Kondo, Hiroki Ichiyama, Nobuto Kitamura, Yoshie Tanabe, Harukazu Tohyama, Akio Minami, Anatomic reconstruction of the anteromedial and posterolateral bundles of the anterior cruciate ligament using hamstring tendon grafts December 2004 Volume 20, Issue 10, Pages 1015-1025
11. Muneta T, Koga H, Mochizuki T, Ju YJ, Hara K, Nimura A, Yagishita K, Sekiya I : A prospective randomized study of 4-strand semitendinosus tendon anterior cruciate ligament reconstruction comparing single-bundle and double-bundle techniques. Arthroscopy. 2007 Jun;23 (6):618-28.
12. Jonathan M. Endoscopic reconstruction for isolated anterior cruciate ligament rupture. J Bone Joint Surg 1998;80-B:288- 94.
13. Kevin D. Reconstruction of the Anterior Cruciate Ligament. J Bone Joint Surg 1998;80-A:184-94.
14. Lysholm J, Gilquist J., Lysholm knee score for ligamentous patients; Am. J Sports Med 1982 10: 150-154
15. R. K. Gupta, Ravi Mittal. Role of Arthroscopy in disorders of knee joint an analysis of 30 cases., Journal of medical education and research Vol. 3 No.3, July-September 2001.
16. Mott HW: Semitendinosus anatomic reconstruction for cruciate ligament insufficiency; Clin Orthop Relat Res. 1983 Jan-Feb; (172):90-2.

DEARMATOFIBROSARCOMA PROTUBERANS IN THE EXTREMITIES: CORRELATION OF FNAC WITH POST-OPERATIVE HISTOPATHOLOGY IN 10 PATIENTS

Kundu P.R.*

Amrita*

Kaur S.*

Kundu Z.S.**

ABSTRACT

Background: Dermatofibrosarcoma protuberans (DFSP) is an uncommon, low-grade, cutaneous sarcoma affecting all age groups and races. The trunk and extremities are common sites of involvement. This retrospective study entails the correlation of fine needle aspiration cytology (FNAC) with histopathology after tumour resection.

Methods: Ten patients (8 males and two female) surgically treated over last 5 years were reviewed retrospectively. All the patients had lesions in the extremities. The pre-operative diagnosis was made using FNAC and correlated with the diagnosis made by histopathology after resection of tumours. The correlation was done by the same pathologist of all the slides.

Results: In eight patients we could correlate the results of FNAC with histopathology in view of the low grade malignancy and in the clinical settings of this lesion. In the rest of the two cases the tumour found to be higher grade on histopathology. Therefore, the efficacy came out to be 80 percent which is good result.

Conclusion: We conclude that DFSP is a low grade malignancy which can be diagnosed on FNAC quite accurately. FNAC is low cost procedure with less morbidity, less complications and easily performed in these superficially located lesions. However it may pose difficulty for the pathologist to differentiate it from other spindle cell tumors. But with appropriate clinical setting and strict diagnostic criteria FNAC can be considered a reliable tool in establishing the diagnosis.

INTRODUCTION

Dermatofibrosarcoma protuberans (DFSP) is a rare, locally aggressive tumor arising from the skin. It is slow growing, locally recurring and rarely metastasizing lesion. It arises from the rearrangement of chromosomes 17 and 22, with the fusion between the collagen type Ia1 gene and the platelet-derived growth factor β -chain gene. Despite its locally aggressive behaviour, DFSP rarely metastasizes. If so, the metastases-free interval is generally long, and metastases are frequently preceded by multiple local recurrences. Approximately 85% to 90% of all DFSPs are low-grade lesions and rest are high-grade fibrosarcomatous lesions with higher risk of metastasis. Fine needle aspiration can diagnose it quite accurately which is low cost procedure with less morbidity, less complications and easily performed in these superficially located lesions. The aim of this study is to correlate FNAC with histopathology after tumour resection in 10 patients of DFSP.

MATERIAL AND METHODS

Fine needle aspiration cytology was performed in

10 cases of the suspected lesions using 21 to 25 G needle and 20 cc syringe without local anaesthetic. The lesion site was cleaned using povidone-iodide solution and ethyl-alcohol (spirit). The most superficial site was selected for aspiration. The needle was inserted inside the lesion. Aspirate was collected in the needle hub and syringe; and immediately slides were prepared as per standard procedure. Aspirate from different portions of the mass lesion was collected by altering the direction of the needle inside the tumor and by giving multiple passes. The slides were air-dried and fixed in alcohol. These were stained by Romanowsky stain (air-dried smears) and by Haematoxylin-eosin stain (alcohol fixed smears) using the standard procedures.

Procedure for Leishman Staining: The air dried smear, film side up was placed on a staining rack (2 parallel glass rods 5 cm apart). Smear was covered with undiluted stain for 1-2 minutes (methyl alcohol fixes the smear). Then it was diluted with distilled water 2 volumes to 1 volume of stain (the best guide was the appearance of metallic scum). This diluted stain was allowed to act for 2-5 minutes. Wherever a phosphate

* Department of Pathology,
BPS Government Medical College for Women,
Khanpur Kalan Sonapat-Haryana

** Department of Orthopaedics,
PGIMS-Rohtak, Haryana -124001

Address for correspondence:
Dr. Mrs Parveen Rana Kundu
Department of Pathology,
BPS Government Medical College for Women,
Khanpur Kalan Sonapat-Haryana

buffer was required for washing, one of pH 6.8 was best. This was substituted for the distilled water when diluting the stain. Then without disturbing the slide, distilled water was flooded over the slide until thinner parts of film were pinkish red. The smear was then dried and mounted. With Leishman stain, the nuclei stained in varying shades of lilac to purple and cytoplasm of cells lilac in colour. The blood cells in the background were soft pink. The smears were cellular showing numerous spindle cells arranged in clustered and scattered singly at places.

Procedure for Haematoxylin and Eosin (H and E) staining: Alcohol fixed smears were stained with Ehrlich's haematoxylin for eight minutes. Differentiation (after a quick rinse in water) was done by dipping the stained slide in 1% acid alcohol (1 ml concentrated HCL in 99 ml of 80% ethyl alcohol). Smears were rinsed with water and blued under running tap water for ten minutes. Smears were then stained with 1% aqueous Eosin Y for two minutes. Smears were rinsed with water. Smears were dehydrated through different grades of alcohol. The dehydrated smears were passed through two baths of xylene. The smears were dried and mounted with disprene 80 dibutylphthalatexylene (DPX) mountant. With haematoxylin and eosin, nuclei stained blue and cytoplasm pale pink. The sections showed spindle cells arranged in storiform pattern with infiltration of subcutaneous fat.

Other stains were used in accordance need and requirement. The slides were examined under microscope using 10x, 40x magnifications. Smears were considered adequate only if a minimum of five clusters of 10 or more, well visualised cells were seen. The

cytopathological diagnosis was made and correlated with histopathological diagnosis in all 10 cases where tissue was available either after surgical resection. In addition to routine H and E stained sections, various histochemical stains were employed to aid in diagnosis wherever required.

RESULTS

The detailed demographic profile of all the 10 patients is described in the Table 1.

Correlation between cytopathological and histopathological diagnosis: In the present study of 10 cases of FNAC in 08 patients we had correlation with the final histopathologic diagnoses where surgical resection was performed. Two patients who were recurrent had high grade lesion on histopathology. In these cases FNAC had suspicion of malignancy but could not conclusively prove them to be high grade DFSP. Thus the efficacy came out to be 80 percent.

DISCUSSION

DFSP is an infrequent tumour which can affect all age groups and races.¹ It is more common in young adult males.² Congenital lesions have been described.³⁻⁶ It can occur anywhere on the body but predominantly seen on trunk and extremities.^{2,7}

They take their origin from fibroblast and represent a low grade sarcoma. Typically characterized by significant subclinical spread, deep invasion and frequent recurrences, they rarely metastasize. They arise just beneath the epidermis as one or several nodules and eventually may grow to form a large, bulky mass.² In 10-

Table 1
The detailed demographic profile of patients

Sr. No.	Age	Sex	Location	Size	FNAC findings	Histopathology findings	Correlation
1.	40	Male	Left thigh	5x5cm	Low grade spindle cell tumor-DFSP	Low grade DFSP	Correlated
2.	60	Male	Left forearm	4x5cm	Low grade spindle cell tumor	Low grade DFSP	Correlated
3.	54	Female	Right shoulder (recurrent)	3x3,1x1 & 2x2cms	Low grade spindle cell tumor	High grade DFSP	Not correlated
4.	24	Male	Left forearm	2.5x2.5cm	Low grade spindle cell tumor	Low grade DFSP	Correlated
5.	44	Male	Left Shoulder (recurrent lesion)	4.5x5.5cm	Low grade spindle cell tumor	High grade DFSP	Not correlated
6.	52	Male	Left Arm	2.5x5cm	Low grade spindle cell tumor	Low grade DFSP	Correlated
7.	26	Male	Left Thigh	3.5x5cm	Low grade spindle cell tumor	Low grade DFSP	Correlated
8.	44	Male	Right arm	4x5cm	Low grade spindle cell tumor	Low grade DFSP	Correlated
9.	42	Male	Right arm	5x4cm	Low grade spindle cell tumor	Low grade DFSP	Correlated
10.	38	Male	Right gluteal area	4x6cm	Low grade spindle cell tumor	Low grade DFSP	Correlated

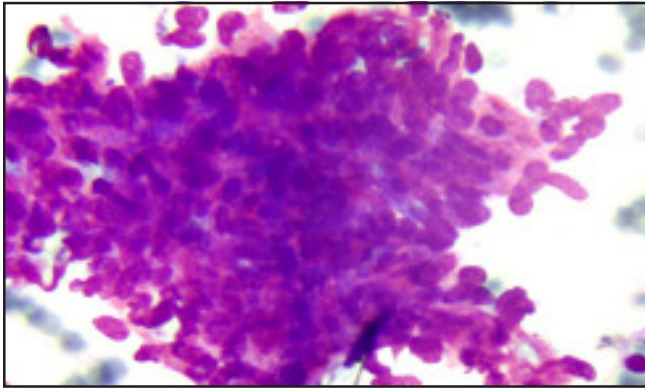


Fig. 1 : FNAC showing clusters of spindle cells

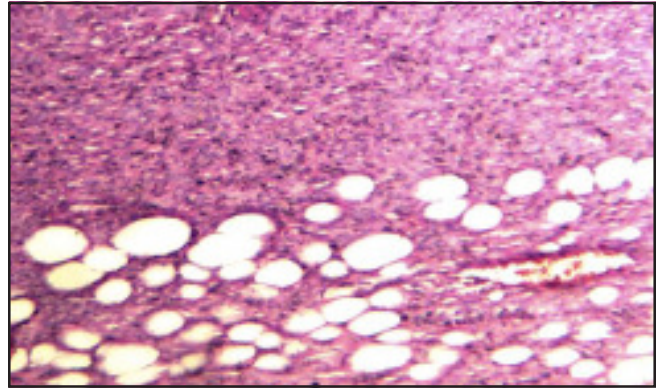


Fig. 2 : Histopathology showing the low grade spindle cell sarcoma with infiltration in dermal fat.

20% a history of trauma can be elicited. Other causes implicated include irradiation, vaccination scars, arsenic exposure, etc.⁷ During pregnancy and around puberty, these tumours may demonstrate accelerated growth, suggesting a hormonal influence. Estrogen and progesterone receptors have been demonstrated in some cases.⁷⁻⁹

The disease usually runs an indolent course and is too often regarded lightly by patients as well as physicians leading to delayed and often too conservative treatment.¹ Typically these tumours present as asymptomatic slow-growing nodules or plaques which may be skin coloured, reddish brown or violaceous.^{2,7} On occasion, however, they may be painful or tender. Atrophic variants resembling morphea have been described. The pigmented variant (Bednar tumour) occurs primarily in blacks and comprises 1-5% of all DFSPs. Although typically slow growing, there may be periods of time when its growth accelerates and gives rise to satellite nodules. In time, multiple satellite nodules may develop, and the tumour may ulcerate or become painful and hemorrhagic.^{2,7} The fully developed lesion is characterized by a subcutaneous plaque superimposed on which are nodules. However, early in its course it may resemble a keloid, cyst or dermatofibroma.^{7,10}

A delay in diagnosis is common. In some series, the tumour was present for >10 years in 30-50% of patients and the average size was 5 cm. FNAC, an incisional or excisional biopsy is mandatory. On microscopic examination, one typically observes numerous monotonous spindle cells arranged in fascicles which form whorls resulting in a storiform pattern.^{2,7} The tumour is usually seated in the deep dermis. Fascicles of cells invade the underlying subcutaneous fat resulting in a honey comb appearance due to the trapping of collections of fat cells. Areas of deep invasion may take

on the appearance of a fibrosarcoma. In these areas, the tumour cells may be arranged in a "herring bone" pattern, and cellular atypia and mitoses may be more common. Some DFSPs may contain areas that display giant cells and resemble a giant cell fibroblastoma, which is thought to be a variant of DFSP occurring in children.⁷ Ultrasound imaging has been used to identify recurrences and assess their extent.¹¹ On MRI, it is a T2-hyperintense with marked enhancement.¹²

The most frequent molecular abnormality observed in DFSP is the formation of a supernumerary ring chromosome or translocation resulting in fusion of the gene encoding the alpha-chain of type 1 collagen, COL1A1 from 17q22, to the platelet-derived growth factor beta-chain, PDGFB gene from 22q13 resulting in autocrine overproduction of the platelet-derived growth factor (PDGF) beta-chain.^{9,13} DFSP are Factor XIIIa negative, CD34 positive, alpha-1-antitrypsin negative, S-100 negative, vimentin positive. In case of myoid variant, actin positive and desmin negative may be observed.^{7,14}

Fine aspiration yield is quite cellular and in forms of clusters. DFSP is a low grade malignancy which can be diagnosed on FNAC quite accurately. Fine aspiration yield is quite cellular and in forms of clusters. FNAC is low cost procedure with less morbidity, less complications and easily performed in these superficially located lesions. However it may pose difficulty for the pathologist to differentiate it from other spindle cell tumours. But with appropriate clinical setting and strict diagnostic criteria FNAC can be considered a reliable tool in establishing the diagnosis.

REFERENCES

1. Bendix-Hansen K, Myhre-Jensen O, Kaae S. Dermatofibrosarcoma protuberans. A clinico-pathological

- study of nineteen cases and review of world literature. *Scand J Plast Reconstr Surg.* 1983;17(3):247-52.
2. Canale S, Beaty J. Tumors. *Campbell's Operative Orthopaedics.* 12th ed. St. Louis, London: Mosby; 2012. p. 970.
 3. Annessi G, Cimitan A, Girolomoni G, Giannetti A. Congenital dermatofibrosarcoma protuberans. *Pediatr Dermatol.* 1993 Mar;10(1):40-2.
 4. Checketts SR, Hamilton TK, Baughman RD. Congenital and childhood dermatofibrosarcoma protuberans: a case report and review of the literature. *J Am Acad Dermatol.* 2000 May;42(5 Pt 2):907-13.
 5. McKee PH, Fletcher CD. Dermatofibrosarcoma protuberans presenting in infancy and childhood. *J Cutan Pathol.* 1991 Aug;18(4):241-6.
 6. Love WE, Keiler SA, Tamburro JE, Honda K, Gosain AK, Bordeaux JS. Surgical management of congenital dermatofibrosarcoma protuberans. *J Am Acad Dermatol.* 2009 Dec;61(6):1014-23.
 7. Rusciani L, Robins R-, Robins P. Malignant tumors of the dermis and subcutaneous tissue. *Textbook of Dermatologic Surgery.* 1st ed. PICCIN; 2012. p. 440-2.
 8. Cakir B, Misirlioglu A, Gideroglu K, Aköz T. Giant fibrosarcoma arising in dermatofibrosarcoma protuberans on the scalp during pregnancy. *Dermatol Surg Off Publ Am Soc Dermatol Surg Al.* 2003 Mar;29(3):297-9.
 9. Bigby SM, Oei P, Lambie NK, Symmans PJ. Dermatofibrosarcoma protuberans: report of a case with a variant ring chromosome and metastases following pregnancy. *J Cutan Pathol.* 2006 May;33(5):383-8.
 10. Ishida M, Okabe H. Fibrosarcomatous pigmented dermatofibrosarcoma protuberans: A case report with review of the literature. *Oncol Lett.* 2012 Sep;4(3):390-2.
 11. Kilian KJ, Ruzicka T, Flaig M, Berking C, Kunte C. [Recurrent fibrosarcomatous dermatofibrosarcoma protuberans. Ultrasound imaging]. *Hautarzt Z Für Dermatol Venerol Verwandte Geb.* 2013 Jul;64(7):512-5.
 12. Millare GG, Guha-Thakurta N, Sturgis EM, El-Naggar AK, Debnam JM. Imaging findings of head and neck dermatofibrosarcoma protuberans. *AJNR Am J Neuroradiol.* 2014 Feb;35(2):373-8.
 13. Fiore M, Miceli R, Mussi C, Lo Vullo S, Mariani L, Lozza L, et al. Dermatofibrosarcoma protuberans treated at a single institution: a surgical disease with a high cure rate. *J Clin Oncol Off J Am Soc Clin Oncol.* 2005 Oct 20;23(30):7669-75.
 14. Arican O, Bakaris S, Bulbuloglu E, Ezberci F. Myoid differentiation and EMA expression in fibrosarcomatous dermatofibrosarcoma protuberans. *Acta Dermatovenerol Alp Pannonica Adriat.* 2006 Mar;15(1):39-44.

FINE NEEDLE ASPIRATION CYTOLOGY OF TUMORS AND TUMOR-LIKE LESIONS OF THE SOFT TISSUES: ITS EFFICACY

Kundu P.R.*

Kalra R.**

Dipti*

Kundu Z.S.***

ABSTRACT

We are reporting our results of fine needle aspiration cytology FNAC for tumors and tumor-like lesions of the soft tissues in 100 patients. In 50 cases the reports of FNAC were correlated with histopathology where open biopsy or surgical resections were performed. We observed that the exact sub-typing/ categorization of the tumors with FNAC alone is difficult. It was observed that sufficient cytological smears were difficult to obtain by aspiration of vascular, densely fibrous, cystic and very large necrotic lesions. FNAC can be used as a preoperative, primary diagnostic modality for soft tissue lesions, but open biopsy may be required for inconclusive lesions. Diagnostic accuracy can be increased with the experience of pathologist and knowledge of the clinical history and the radiologic findings.

INTRODUCTION

Soft tissue can be defined as nonepithelial extraskelatal tissue of the body exclusive of the reticuloendothelial system, glia and supporting tissue of various parenchymal organs. The voluntary muscles, fat, and fibrous tissue along with the vessels serving these tissues represent it. By convention, it also includes the peripheral nervous system because tumors arising from nerves present as soft tissue masses and pose similar problem in differential diagnosis and therapy. Benign mesenchymal tumors outnumber sarcomas by a factor of at least 100 and they have a very high cure rate after surgical excision. Malignant mesenchymal neoplasms amount to less than 1% of the overall human burden of malignant tumors but they are life threatening and may pose a significant diagnostic and therapeutic challenge since there are more than 50 histological subtypes of soft tissue sarcomas. For diagnosis of these tumors several biopsy techniques are available, The choice of biopsy is dictated by the size and location of mass and the experience of the pathologist. Fine needle aspiration cytology (FNAC) has become an established tool in the diagnostic armamentarium of many clinical practices. The published literature on role of FNAC in diagnosis of soft tissue tumors and tumor-like lesions includes only a few larger series and some individual case reports. We in this study assessed the role of FNAC in tumor and tumor-like lesions of soft tissues.

MATERIAL AND METHODS

This study was conducted in the Department of Pathology at our institute including 100 patients of both sexes of all age groups with clinically diagnosed tumors and tumor-like conditions of the soft tissues. The patients with lesions of musculo-skeletal regions in extremities and other sites were included. The lesions inside the body cavities and those lesions which were clinically suspected to be tumor or tumor-like lesions of soft tissues but later came out to be the inflammatory, infections or parasitic masses were excluded from the study. The primary tumors of epithelial or skin adenexal in origin were also excluded from the study.

The FNAC was performed in all 100 cases in out-patient department using 21 to 25 G needle and 20 cc syringe without local anesthetic. The lesion site was cleaned using povidone-iodide solution and ethyl-alcohol (spirit). The most superficial site was selected for aspiration. The needle was inserted inside the lesion. Aspirate was collected in the needle hub and syringe; and immediately slides were prepared as per standard procedure. Aspirate from different portions of the mass lesion was collected by altering the direction of the needle inside the tumor and by giving multiple passes. The slides were air-dried and fixed in alcohol. These were stained by Romanowsky stain (air-dried smears) and by Haematoxylin-eosin (H and E) stain (alcohol fixed smears) using the standard procedures. Other stains

* Department of Pathology,
BPS Government Medical College for Women,
Khanpur Kalan Sonapat-Haryana

** Department of Pathology,
PGIMS-Rohtak, Haryana

*** Department of Orthopaedics,
PGIMS-Rohtak, Haryana -124001

Address for correspondence:
Dr. Mrs Parveen Rana Kundu
Department of Pathology,
BPS Government Medical College for Women,
Khanpur Kalan Sonapat-Haryana

were used in accordance to the type of the lesion and requirement. The slides were examined under microscope using 10x, 40x magnifications. Smears were considered adequate only if a minimum of five clusters of 10 or more well visualised cells were seen. The cytopathological diagnosis was made and correlated with histopathological diagnosis in 50 cases where tissue was available either after open biopsy/ surgical resection. In addition to routine H and E stained sections, various histochemical stains were employed to aid in diagnosis wherever required.

RESULTS

The present study was performed on 100 patients of soft tissue tumors and tumor-like lesions. The patients with soft tissue tumors and tumor-like lesions of the extremities, back and those of head and neck region were included in the study. However, the lesions of body cavities and those after cytological examination proved to be either inflammatory, epithelial or infectious like parasitic ones were excluded from the study. Fine needle aspiration cytology (FNAC) was performed for all these lesions at the FNAC clinic of the department. Out of these 100 patients, in fifty cases we had the opportunity to correlate the findings of cytology with histopathology; where the lesions were either resected or open biopsies were taken. In the rest of the fifty patients, only cytological examination was done, where the lesions were either not subjected to surgery like lipomas or after FNAC were treated with chemotherapy and/or radiation and hence tissue for histopathological examination was not available.

Table 1
Site of the Lesions (n=100)

Site of the lesions	Benign lesions	Malignant lesions	Number of patient
Upper Extremity			37
Shoulder	4	3	7
Arm	9	6	15
Forearm	3	3	6
Hand/wrist	9	0	9
Lower Extremity			45
Gluteal	4	4	8
Thigh	4	15	19
Knee/Popliteal	3	0	3
Leg	7	4	11
Foot/ankle	3	1	4
Back	7	4	11
Head and Neck	4	2	6
Chest wall	0	1	1
Total	57	43	100

Table 2
Cytological Diagnoses (n=100)

Type of Lesion on FNAC	Number of Cases	Percentage
Lipomas	22	22
Malignant mesenchymal tumors	21	21
Benign spindle cell lesions	14	14
Neurofibromas	9	9
Spindle cell neoplasms with undetermined behaviour	7	7
Giant cell tumor (GCT) of tendon sheaths	5	5
Metastatic deposits	4	4
Liposarcomas	3	3
Malignant fibrous histiocytomas (MFH)	1	1
Hibernoma	1	1
Nodular fasciitis	1	1
Rhabdomyosarcoma	1	1
Alveolar soft part sarcoma	1	1
Fibrosarcoma/ synovial sarcoma	1	1
Fibromatosis	1	1
Benign vascular neoplasm	1	1
Inadequate aspirates	7	7
Total	100	100

Table 3
Efficacy of FNAC in tumor and tumor-like lesions of soft tissues

Parameters	Results of fine needle aspiration	
	Excluding suspicious cases (n=36)	Including suspicious cases (n=43)
Sensitivity	94%	96%
Specificity	100%	100%
Positive predictive accuracy	100%	100%
Negative predictive accuracy	95%	95%

Table 2 shows the analysis of cytopathological diagnosis of soft tissue tumors and tumor-like lesions, excluding and including suspicious cases respectively for statistical calculation. Cases labelled as inadequate for comments are not included. When cases suspicious of malignancy were included, sensitivity and specificity were 96% and 100% respectively while positive predictive accuracy and negative predictive accuracy came out to be 100% and 95% respectively.

DISCUSSION

The diagnosis of soft tissue tumors is difficult due to great variety of histologic types and frequent similarities within different lesions. In fine needle aspiration cytology (FNAC), these problems are exacerbated due to limited cytologic expression of the tumor.. Open biopsy provides full histologic architecture of the lesion to the pathologists as well as cytologic features, but it may possibly induce tumor cell seedings within the wound and require more extensive margins of the lesions at surgery.

Even though the literature on FNAC of soft tissue masses is relatively scarce, a large amount of interest has developed in their area in last few years due to economy of the procedure, low incidence of complications, feasibility and high therapeutic efficiency.

The common site of the soft tissue tumors include the extremities, trunk wall and retroperitonium. The commonest site of involvement in our series included thigh (n=19), followed by arm (n=15), back (n=11) and leg (n=11). Nagira et al in their study of FNAC of 301 soft tissue lesions, observed the locations as: thigh (n=92), trunk (n=65), leg (n=39), arm (n=38), foot (n=26), hand (n=21) and in the forearm (n=20). The sarcomatous (malignant) lesions were mainly present in the thigh, gluteal and arm regions. Further, it was noted that in the acral parts of extremities, the benign lesions outnumbered the malignant ones.

100 cases were adequate for cytodiagnosis and 7 (7%) were inadequate. Ackerman et al reported that 20 of 365 aspirates (5.5%) were not diagnostic while in the series reported by Layfield et al the incidence of insufficient tissue fragments was 17% i.e. 22 out of 136 aspirates. Nagira et al reported 22 (7%) inadequate

smears in a series of 301 cases. In our study these 7 inadequate aspirates on histopathological examination turned out to be malignant fibrous histiocytomas in two cases; and one each of malignant peripheral nerve sheath tumor, angiomatoid MFH, nodular fasciitis, fibroma of tendon sheath and hemangioma. This inadequacy could be explained on the basis of the fact that in malignant lesions of larger size, there was lot of necrosis and cystic changes within the lesion. In the benign category the aspirates were inadequate in lesions which were angiomatous MFH; and from those which were more densely fibrous/collagenised

Cytopathological Analysis: In the present study out of 100 cases, in 93 patients the aspirates were adequate. Cytopathologically the commonest lesions were lipomas in 22 cases (22%), malignant mesenchymal tumors 21 cases (21%), benign spindle cell lesion 14 (14%) and neurofibromas 9 (9%). Overall, out of 93, there were 54 benign lesions, 32 malignant lesions and 7 spindle cell neoplasm with undetermined possibly malignant behavior and 7 aspirates were inadequate for comments. Out of 93 adequate aspirates in 51 cases a type specific diagnosis could be ascertained. In rest 42 only biological behaviour could be determined but it was not possible to give type specific diagnoses. The cytomorphologic classification of various FNA diagnoses of 279 cases in the series of Nagira et al, there were 62 benign spindle cell lesions, 28 lipomas and 20 malignant pleomorphic lesions, constituting the major number of these lesions after exclusion of epithelial and inflammatory lesions. Dey et al in their retrospective study of histopathologically proven cases of FNAC of soft tissue tumors, were able to correctly categorize only 22 of 47 cases (46.8%). In our study, out of 93 adequate aspirates of soft tissue tumors, we could correctly categorize the lesions in 51 (54.8%) cases.

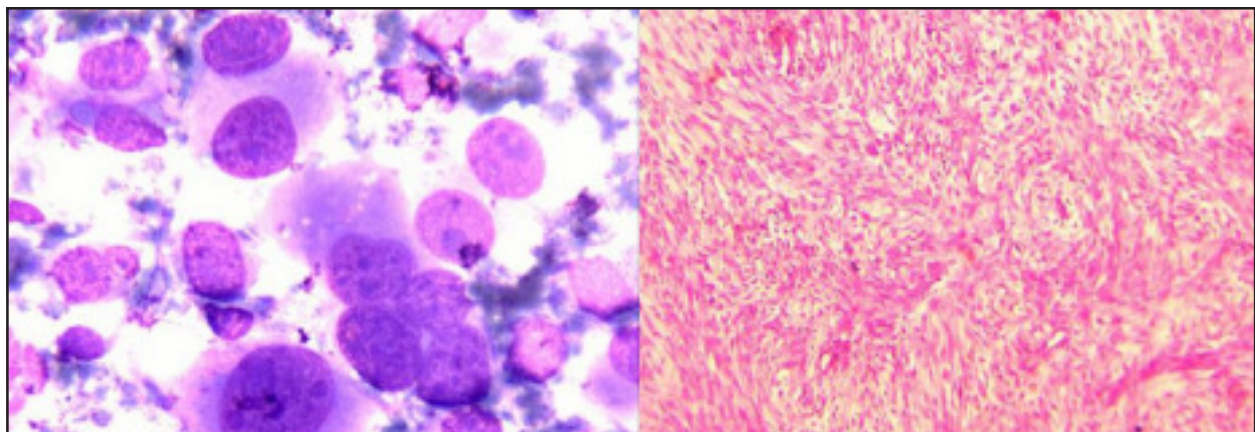


Fig. 1 : FNAC and histopathology of malignant fibrous histiocytoma

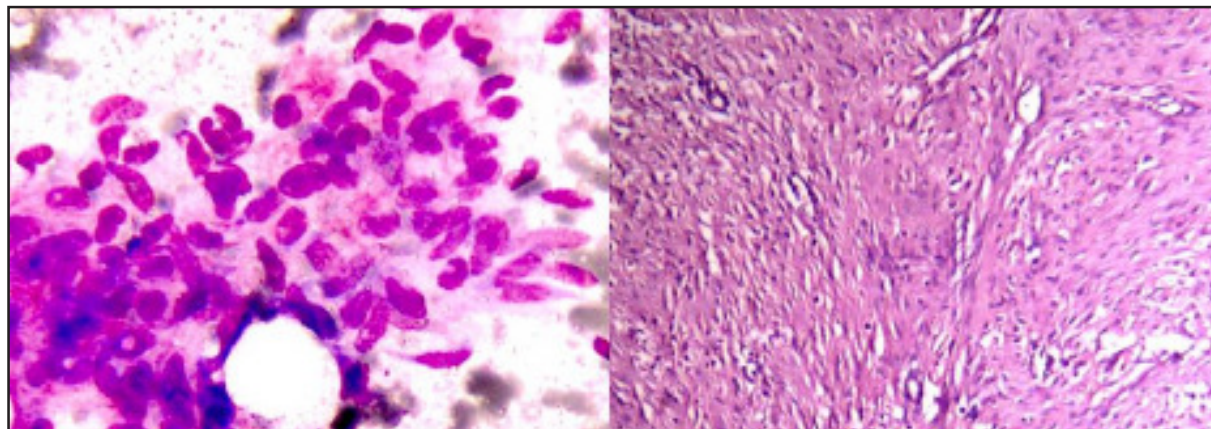


Fig. 2 : FNAC and histopathology of nodular fasciitis.

Correlation between cytopathological and histopathological diagnosis: In the present study of 100 cases of FNAC in 50 patients we could have final histopathologic diagnoses where either an open biopsy or surgical resection was performed. Histopathologically the commonest diagnosis in our series was malignant fibrous histiocytoma in 16 cases, out of total 29 malignant tumors. The other 21 were benign soft tissue lesions. This finding of having more malignant tumors than the benign is due to fact that such lesions are surgically resected more than the benign lesions. On the other hand, many of the benign lesions like lipomas and neurofibromas can be kept under observations and need not be resected.

Efficacy and reliability of FNAC: In the present study fine needle aspirations were performed for the soft tissue tumors and tumor-like lesions in 100 cases, out of which in 50 cases, histopathological examination was also done. Thus the results in these 50 cases of FNAC could be correlated with histopathology and the efficacy and reliability of FNA's could be evaluated in these cases. Out of these 50 cases in 43 the yield of material was adequate for the comments. There were 19 benign, 17 malignant and seven cases of undetermined biological behaviour; suspicious of malignancy. However, on final histopathological diagnosis one case out of 19 benign lesions turned out to be malignant i.e. dermatofibrosarcoma protuberans. When we considered our diagnosis in view of benign/ malignant and also including the cases suspicious of malignancy, the sensitivity and specificity for a diagnosis of malignant lesions were 96% and 100% respectively with positive and negative predictive values 100% and 95% respectively. However, after exclusion of suspicious cases, the sensitivity and

specificity was 94% and 100% respectively with positive predictive accuracy and negative predictive accuracy of 100% and 95% respectively. The results are comparable with other studies.

CONCLUSIONS

After analyzing the results of fine needle aspiration cytology for the soft tissue tumors and tumors-like lesions in the extremities, back, chest wall and head and neck region and after comparing the results with various reported studies, we can arrive at a conclusion that FNAC is a valuable technique for distinguishing malignant from benign soft tissue lesions. However, the exact sub-typing/ categorization of the tumors with FNAC alone is difficult. It was observed that sufficient cytological smears were difficult to obtain by aspiration of vascular, densely fibrous, cystic and very large necrotic lesions. FNAC can be used as a preoperative, primary diagnostic modality for soft tissue lesions, but open biopsy may be required for inconclusive lesions. Diagnostic accuracy can be increased with the experience of pathologist and knowledge of the clinical history and the radiologic findings.

REFERENCES

1. Geisinger KR, Abdul-karim FW. Fine needle aspiration cytology of soft tissue tumors. In: Weiss SW, Goldblum JR, eds. Enzinger and weiss's soft tissue tumors. 4th ed. Missouri: Mosby Inc 2001: p. 147-88.
2. Fletcher CDM, Rydholm A, Singer S, Sundaram M, Coindre JM. Soft tissue tumors: epidemiology clinical features, histopathological typing and grading. In: Fletcher CDM, Unni KK, Mertens F eds. World Health Organisation classification of tumors: pathology and genetics of tumors of soft tissue and bone. IARC Press: Lyon 2002: p.10-8.

FINE NEEDLE ASPIRATION CYTOLOGY OF TUMORS AND TUMOR-LIKE LESIONS OF THE SOFT TISSUES: ITS EFFICACY

3. Kumar V, Abbas AK, Fausto N. Neoplasia. In: Kumar V, Abbas AK, Fausto N, editors. *Robins and Cotran pathologic basis of disease*. 7th ed. New Delhi: Elsevier 2004: p.269-342.
4. Martin HE, Ellis EB. Biopsy by needle puncture and aspiration. *Ann Surg* 1930; 92: 169-81.
5. Nagira K, Yamamoto T, Akisue T, Marui T, Hitora T, Nakatani T et al. Reliability of fine-needle aspiration biopsy in the initial diagnosis of soft tissue lesions. *Diagn Cytopathol* 2002; 27: 354-61.
6. Silverberg SG, Wick MR. General philosophy and principles of surgical pathology and cytopathology, including quality and malpractice issues. In: Silverberg SG, DeLeillis RA, Frable WJ, LiVolsi VA, Wick MR, editors. *Silverberg's principles and practice of surgical pathology and cytopathology*. 4th ed. New York: Elsevier 2006: p.1-14.
7. Akerman M, Rydholm A, Persson BM. Aspiration cytology of soft tissue tumors: the 10 years experience at an orthopaedics oncology center. *Acta Orthop scand* 1985; 56: 407-12.
8. Bennert KW, Abdul-Karim FW. Fine needle aspiration cytology vs needle core biopsy of soft tissue tumors: a comparison. *Acta Cytol* 1994; 38: 381-4.
9. Layfield LJ, Anders KH, Glassgow BJ, Mirra JM. Fine needle aspiration of primary soft tissue lesions. *Arch Pathol Lab Med* 1986; 110: 420-4.
10. Dey P, Mallik MK, Gupta SK, Vasishta RK. Role of fine needle aspiration cytology in the diagnosis of soft tissue tumors and tumor-like lesions. *Cytopathol* 2004; 15: 32-7.
11. Domanski HA, Akerman M, Engellau J, Gustafson P, Mertens F, Rydholm A. Fine needle aspiration of neurolemoma (schwannoma): a clinicopathologic study of 116 patients. *Diagn Cytopathol* 2006; 34:403-12.
12. Laforga JB. Cellular schwannoma: report of a case diagnosed intraoperatively with the aid of cytologic imprints. *Diagn Cytopathol* 2003; 29:95-100.
13. Akerman M, Ryd W, Skything B. Fine needle aspiration of synovial sarcoma: Criteria for diagnosis: retrospective reexamination of 37 cases including ancillary diagnostics: a Scandinavian sarcoma group study. *Diagn Cytopathol* 2003; 28:232-38.
14. Gupta K, Dey P, Vasishta RK. Fine needle aspiration cytology of malignant peripheral nerve sheath tumors. *Diagn Cytopathol* 2004; 31: 1-4.
15. Domanski H. Cytologic features of angio-leiomyoma: cytologic-histologic study of 10 cases. *Diagn Cytopathol* 2002; 27:161-6.
16. Palmer HE, Mukunyadz P, Culbreth W, Thomas RJ. Subgrouping and grading of soft-tissue sarcomas by fine-needle aspiration cytology: a histopathologic correlation study. *Diagn Cytopathol* 2000; 24:307-16.
17. Campora RG, Arias GM, Salaverri CO, Heras MJ, Alvarez EC, Pascual AG et al. Fine needle aspiration cytology of primary soft-tissue tumors: morphologic analysis of the most frequent types. *Acta Cytol* 1992; 36:905-17.
18. Kilpatrick SE, Ward WG, Cappellari JO, Bos GD. Fine needle aspiration biopsy of soft tissue sarcomas: a cytomorphologic analysis with emphasis on histologic subtyping grading and therapeutic significance. *Am J Clin Pathol* 1999; 112:179-88.
19. Ordonez NG, Hickey RC, Brooks TE. Alveolar soft part sarcoma: a cytologic and immunohistochemical study. *Cancer* 1988; 61:525-31.
20. Ferrer PL, Jimenez-Heffernan JA, Vicandi B, Gonzalez-Peromato P, Viguer JM. Cytologic features of alveolar soft part sarcoma: report of 3 cases. *Diagn Cytopathol* 2002; 27:115-9.
21. Gupta N, Rajwanshi A, Nijhawan R, Srinivasan R, Malhotra S. Metastatic granulosa cell tumor: diagnosed by fine needle aspiration cytology. *Diagn Cytopathol* 2005; 34 (6): 453-4.
22. Iyer VK, Kapila K, Verma K. Fine needle aspiration cytology of giant cell tumor of tendon sheath. *Diagn Cytopathol* 2003; 29:105-10.
23. Gupta K, Dey P, Goldsmith R, Vasishta RK. Comparison of cytologic features of giant cell tumor and giant cell tumor of tendon sheath. *Diagn Cytopathol* 2004; 30: 14-8.
24. Dodd LG, Martinez S. Fine needle aspiration cytology of pseudosarcomatous lesions of soft tissue. *Diagn Cytopathol* 2001; 24:28-35.
25. Sapi Z, Antal I, Papai Z, Szendroi M, Mayer A, Jakab K et al. Diagnosis of soft tissue tumors by fine needle aspiration with combined cytopathology and ancillary techniques. *Diagn Cytopathol* 2002; 26:232-42.
26. Klijanienko J, Caillaud JM, Lagace R. Fine needle aspiration of primary and recurrent dermatofibrosarcoma protuberans. *Diagn Cytopathol* 2004; 30: 261-5.
27. Lemos MM, Karlen J, Tani E. Fine needle aspiration cytology of angiomatoid malignant fibrous histiocytoma. *Diagn Cytopathol* 2005; 33: 116-21.
28. Vielh P. Technique of FNA cytology. In: Orell SR, Sterett GF, Whitaker D, editors. *Fine needle aspiration cytology*. 4th ed. New Delhi: Churchill Livingstone 2005: p.9-31.
29. Inwood MJ, Thomson S. Basic hematologic techniques. In: Raphael SS, editor. *Lynch's medical laboratory technology*. 3rd ed. Philadelphia: WB Saunders 1976: p.1073-1129.
30. Culling CFA. Histology. In: Raphael SS, editor. *Lynch's medical laboratory technology*. 3rd ed. Philadelphia: WB Saunders 1976: p.916-33.

BILATERAL ILIOUMBAR LIGAMENTS' OSSIFICATION IN ANKYLOSING SPONDYLITIS

Nath S.

ABSTRACT

A 46 years old female presented 7 years ago with low backache. Radiologically, there was Bilateral Ilioumbar Ligaments' Ossification showing pseudoarthrosis on the left side in its middle. The pain persisted without any other signs and symptoms clinically and radiologically. Fresh X-rays after 7 years show early signs of Ankylosing Spondylitis. Very rare cases of this entity are reported in the literature; hence, the case is being presented

Keywords: Ilioumbar Ligaments' Ossification, Ankylosing Spondylitis.

INTRODUCTION

Lapadula¹ et al in 1991 from (University of Bari) Italy reported one case of a 21 years old woman with clinical picture of HLA-B27+ reactive arthritis (ReA) in which the ossification of the left iliolumbar ligament was detected.

Later in 1997 from a different centre Bologna from Italy again Oliveri² et al reported a case of 52 years old man suffering from undifferentiated seronegative spondyloarthropathy (uSpA) without spine involvement showed bilateral Ilioumbar Ligaments' Ossification.

Apart from above two reports no other rheumatologic report is available showing Ilioumbar Ligaments' Ossification. The present case shows quite unusual features for which it is being presented.

CASE REPORT

A 46 years old female (Mrs. K.C.), mother of 4 male children, housewife presented to us 7 years ago for low backache. Clinically spine was normal. X-Rays showed Bilateral Ilioumbar Ligaments' Ossification with pseudoarthrosis in its middle on the left side. No other radiological findings were present. She was put on NSAID and Spinal Extension Exercises. Next year she got operated by General Surgeons for gall stones. Cholecystectomy was done. The back pain persisted in slightly to the Right side of midline for which General Surgeons got X-Rays KUB done to R/O ureteric calculus. At the same time, because her complaint of neck pain X-

Rays of Cervical spine were also taken. X-rays showed all the features of Cervical Spondylosis and absence of ureteric calculus, it was confirmed by IVP after admission by Urologist. Isometric Neck Exercises were started for Cervical Spondylosis. Later she developed hypertension for which antihypertensive were started by physician.

After the marriage of her eldest son she developed pain in the knees. Clinically & radiologically she was suffering from Osteoarthritis, more severe on the left side as compared to the right. Quadriceps exercises and orally glucosamine was added to NSAID. The backache was persisting even now, though clinically spine was normal. Hence, fresh X-Rays of Lumbosacral spine and both S.I. joints with C.T.Scan of Iliolumbar ligaments & L5 vertebra were taken.

Radiological finding were bilateral Ilioumbar Ligaments' Ossification with pseudoarthrosis on the left in its middle which was also confirmed by C.T. Scan (Fig 4 & 5). Both Sacroiliac joints were normal (Fig. 3 & 4). L5-S1 Subluxation and fusion of bodies was seen (Fig 2). There was Bridging of L1-L2 on Anterior, Posterior and Right side (Fig 1 & 2) suggestive of early Ankylosing Spondylitis. There was no squaring of vertebrae. Clinically spinal movements did not show restriction of movements. Chest Expansion was one-and-a half inches. The Blood reports were

- Hb - 11.6 gm%, ESR - 20/1st hour, TLC - 7000/
Cu.mm, DLC - P-55, L-40E-05, M-Nil

ASO -ve, CRP -ve, RA -ve, HLA -B27 was +ve(Positive). Clinically all joints were symptom free.

* Deptt of orthopaedics
Shri Balaji Trauma and Superspecialty Hospital

Address for correspondence:
Dr. Satadal Nath
Deptt of orthopaedics
Shri Balaji Trauma and Superspecialty Hospital
Korba (C.G.)

BILATERAL ILIOUMBAR LIGAMENTS' OSSIFICATION IN ANKYLOSING SPONDYLITIS

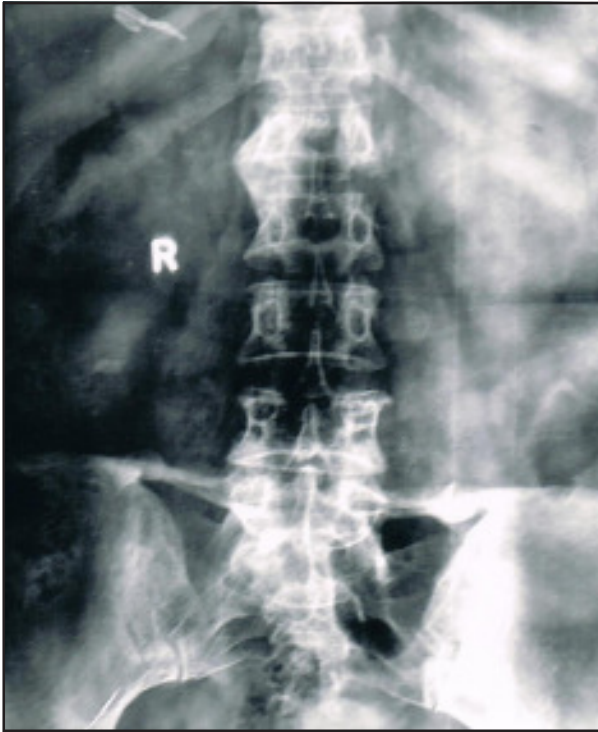


Fig. 1 : Iliolumbar ligament ossification. LS on both sides. Bridging of bone SpineAP L1-L2 vertebrae.

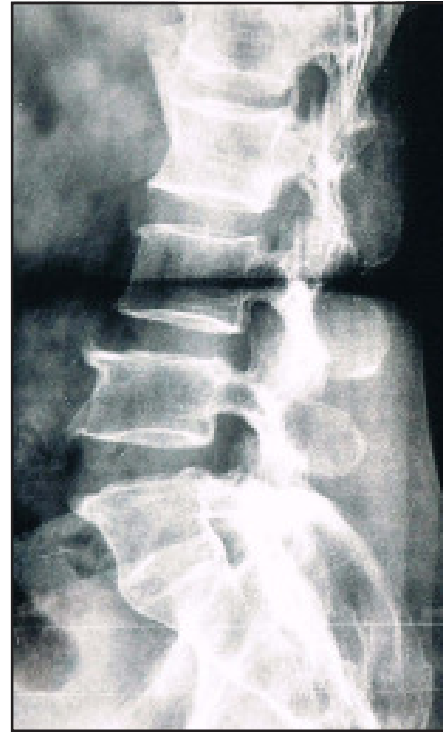

Fig. 2 : Bridging of L1-L2 vertebrae LS Subluxn and fusion L5-S1 Spine-Lat

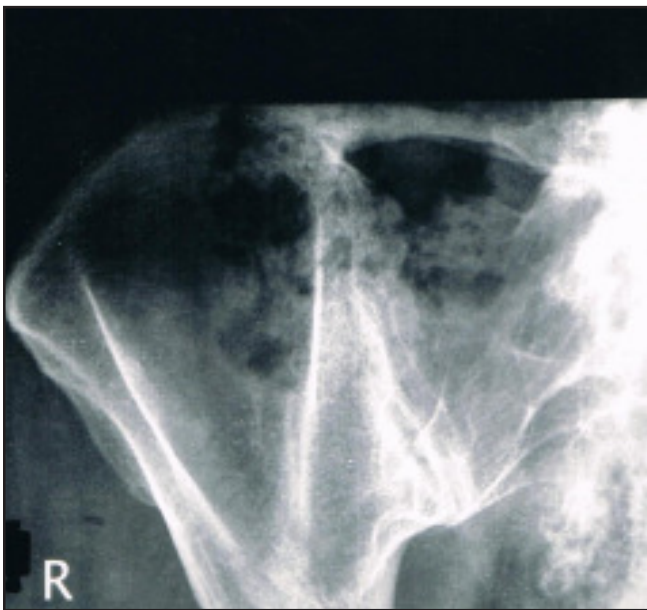


Fig. 3 : Iliolumbar ligament ossification. S.I. jt(R) S.I. joint- normal Oblique

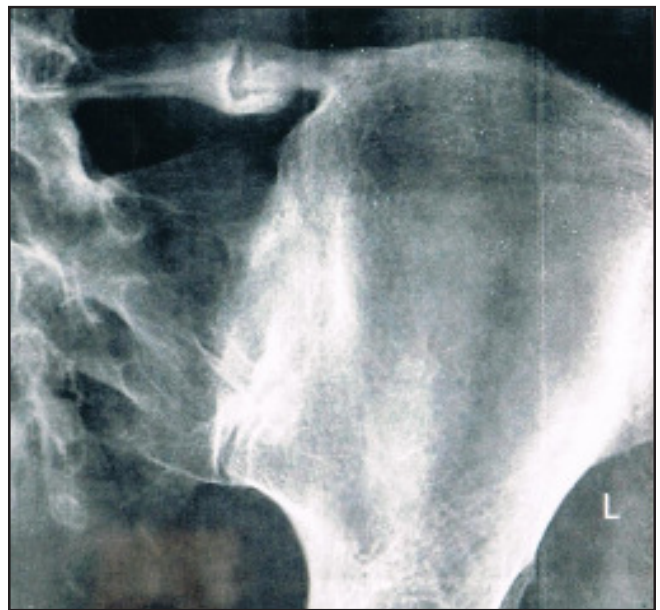


Fig. 4 : S.I. joint- normal Iliolumbar ligament ossification. S.I. jt (L) with pseudoarthrosis Oblique

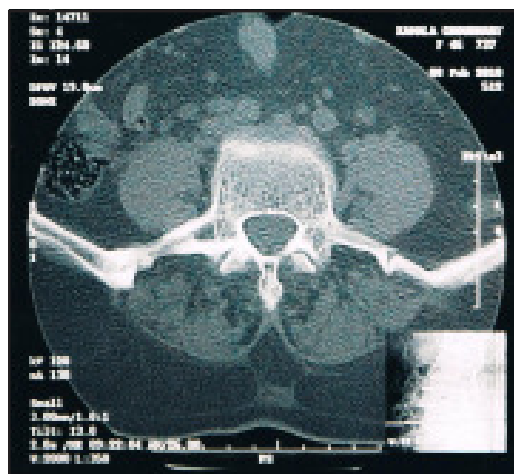

Fig. 5 : Iliolumbar ligament ossification. C.T. With pseudoarthrosis on the left side Scan

DISCUSSION

The Ankylosing Spondylitis is more common in males than in females. Clinically movements are restricted like a bamboo earlier than radiological findings of Sacroiliac joints affection and bone bridging of L1-L2. Chest Expansion also is diminished clinically quite early. The age of onset is not that late.

The present case, though the radiological features in the form of bony bridging of L1-L2 appeared first than the clinical features, they appeared quite late, especially at the age of 46 years. Other radiological features like sacro-iliac joints involvement and squaring of vertebrae are missing.

In the literature, to study the role of iliolumbar ligaments in the body; its development, anatomy; histology and biomechanical studies have been carried out. This ligament is muscular in the newborn and becomes ligamentous only from 2nd decade, being formed by metaplasia from the fibers of the quadratus lumborum muscle. By 3rd decade the definitive ligament is formed.³

In one study, because of gender difference⁴ -in one group (Type A) The Anterior and Posterior ligaments had separate courses. While (Type B) Anterior and Posterior ligaments moved together. Hanson⁵ et al found morphological features of iliolumbar ligaments differed in Black people from White people. The ligament in Black people was inserted on the L5 pedicle and was made up of one single, large ligament. However, the ligament in white people was inserted on the L5 transverse process and consisted of two considerably smaller but distinctly separate ligaments. They also reported that the ligament was oriented more horizontally in Black people than in White people.

This ligament is thought to provide additional stability to the Lumbosacral junction. Biomechanical studies have suggested the ligament restrains motion at the L5-S1 level, especially in flexion and lateral bending.^{3,6,7} Alteration in the morphological features of the iliolumbar ligaments is a contributory factor in lower lumbar disc degeneration and slippage in patients with spondylolisthesis at the L5-S1 as is evident in our case (Figure 2).

REFERENCES

1. Lapadula G, Covelli M, Numo R, Pipitone V. Iliolumbar ligament ossification as a radiologic feature of reactive arthritis. *J Rheumatol* 1991 Nov 18(11):1760-2
2. Oliveri I, Padula A, Pierro A, Barozzi L, Ferri S, Pavlica P. Iliolumbar ligament ossification in undifferentiated seronegative spondyloarthropathy. *Clin Rheumatol* 1997 Mar 16(2):212-4.
3. Luk K D, Ho H C, Leong J C Y. The iliolumbar ligament. A study of its anatomy, development and clinical significance. *J Bone Joint Surg* 1986; 68B:197-200.
4. Fujiwara A, Tamai K, Yoshida H, Kurihashi A, Saotome K, An H S, Lim T H. Anatomy of the iliolumbar ligament. *Clin Orthop Related Res* 2000 Nov, (380):167-72.
5. Hanson P, Magnusson S P, Sorensen H, Simonsen E B. Differences in the iliolumbar ligament and the transverse process of L5 vertebra in young white and black people. *Acta Anat* 1998, 163:218-23.
6. Yamamoto I, Panjabi M M, Oxland T R, Crisco J J. The role of the iliolumbar ligament in the Lumbosacral junction. *Spine* 1990; 15:1138-41.
7. Fujiwara A, Tamai K, Kurihashi A, Yoshida H, Saotome K. Relationship between morphology of iliolumbar ligament and lower lumbar disc degeneration. *J Spinal Disord* 1999; 12:348-52

FOREIGN BODY GRANNULOMA CAUSING CHRONIC OSTEOMYELITIS OF THE METATARSAL - A CASE REPORT

Agrawal A. C. *

Sahu C. **

Sahoo B. **

Jain A. **

ABSTRACT

Foreign body granuloma is a tissue reaction for retained foreign bodies after skin-penetrating trauma. Many are caused by thorns or by fragments of wood that are retained in the foot. The differential diagnosis for bony reaction to an unrecognised organic foreign body includes osteoid osteoma, chronic and acute osteomyelitis, tuberculosis granuloma, bone cyst, aneurysmal bone cyst, cortical ?brous defect, and neoplasm. We report the case of a 32 year old male su?ering from a fragment of wood inducing multiple lytic lesion of the fourth metatarsal that demonstrates the diagnosis difficulties of foreign body granuloma.

INTRODUCTION

Penetrating wounds of the foot are very common in the rural areas in India because people walk barefoot. In most cases it is caused by thorns, nails, fragments of wood that are retained in the foot causing cellulitis, abscess formation and after long duration foreign body granuloma. In our country many people residing in rural areas rarely seek medical advice for minor trauma like puncture wound. After long duration they present with foreign body granuloma, osteomyelitis due to small fragment of wood or thorns. Pain and swelling are the main concerns for which they seek medical advice. Here we present case of a 32 year old male su?ering from a fragment of wood inducing multiple lytic lesion of the fourth metatarsal.

CASE REPORT

A 32 year old male presented with swelling in dorsolateral region of right foot. He recalls history of penetrating trauma on his sole by a wood 2 yrs back. After injury he himself removed the wood and had mild bleeding and pain. So he went to local health worker and was prescribed 2-3 days of medication and he was relieved of all complaints after taking medicines. 2 months later he developed pain and swelling on the dorsolateral aspect of his right foot. Pain and swelling increased on working and relieved by rest. He didn't take any medical advice for it for about 1½ years. Later by the end of 2yrs he developed persistent swelling and pain in

the region. Therefore he went to local orthopaedic surgeon who prescribed him 5 days of medication, but pain was not relieved. So he was advised an x ray. Physical examination of the patient showed a healthy patient with mild swelling on dorsolateral aspect of right foot. Swelling was roughly 3×4 CM with ill-defined borders. Skin over swelling was intact. No discharging sinus was present. Mild tenderness was present. No local rise in temperature was present. No tenosynovitis or local oedema was present. Distal neurovascular status was normal. Laboratory investigations were in normal range. CRP, ESR was in normal limits. WBC counts were in normal range. Radiograph showed multiple lytic lesions along the shaft of fourth metatarsal with sclerotic changes. CT scan suggested multiple areas of bony defects in the cortex along the medial and plantar aspect associated with sclerotic changes in right 4th metatarsal. Margins of the cortical defects are smooth. The dorsum of this metatarsal shows soft tissue swelling with enhancement indicating fibrosis. Rest of the foot was normal.

Surgical exploration was done by dorsal approach over 4th metatarsal. A fragment of pine leaf stick from a broom stick measuring around 4mmx 2 mm in size was removed. Granulation tissue surrounding it was removed. The shaft of the metatarsal with cortical defect was excised. Fibular graft was taken from the same side and reconstruction of the 4th metatarsal was done. The limb was kept in a short leg cast for healing.

* Prof. & HOD, Orthopaedics
AIIMS Raipur CG
** Senior Resident
AIIMS Raipur CG

Address for correspondence:
Prof. Dr. Alok C. Agrawal
Prof. & HOD
Dept. of Orthopaedics
All India Institute of Medical Sciences,
Raipur CG

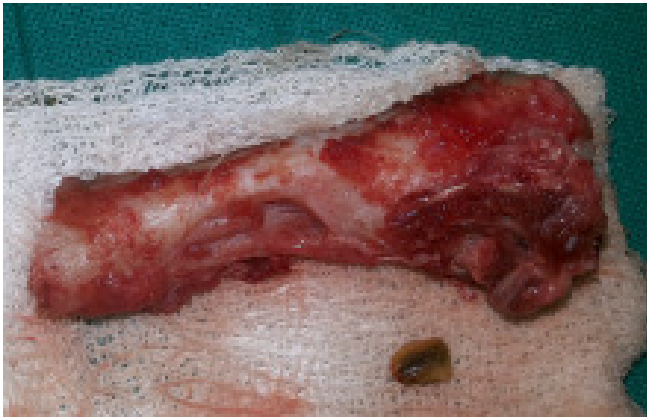

Fig. 1 : Excised bamboo stick and Metatarsal.

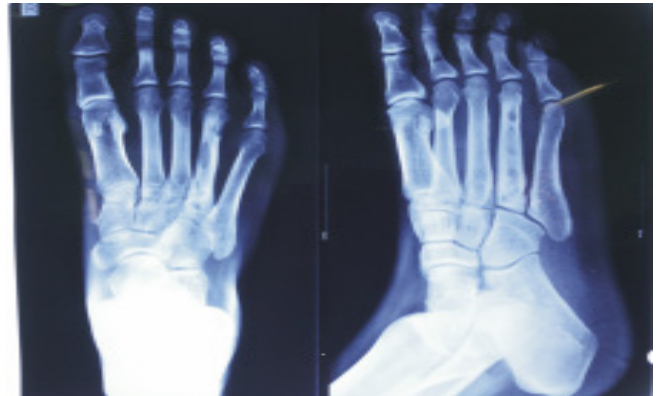


Fig. 2 : Chronic Osteomyelitis of the 4th metatarsal as seen on X-Ray

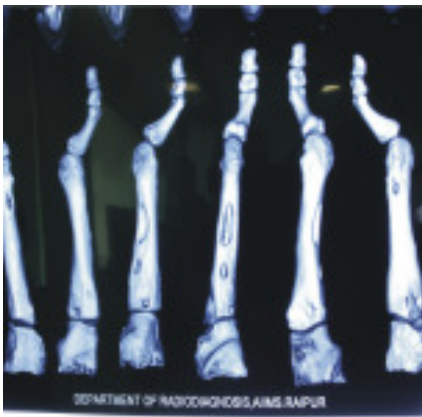


Fig. 3 : Chronic Osteomyelitis of the metatarsal as seen on C T Scan images

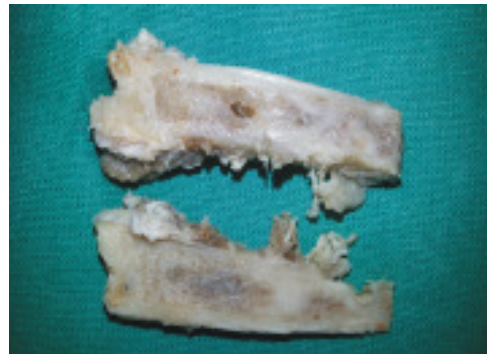


Fig. 4 : Chronic Osteomyelitis evident in excised specimen.

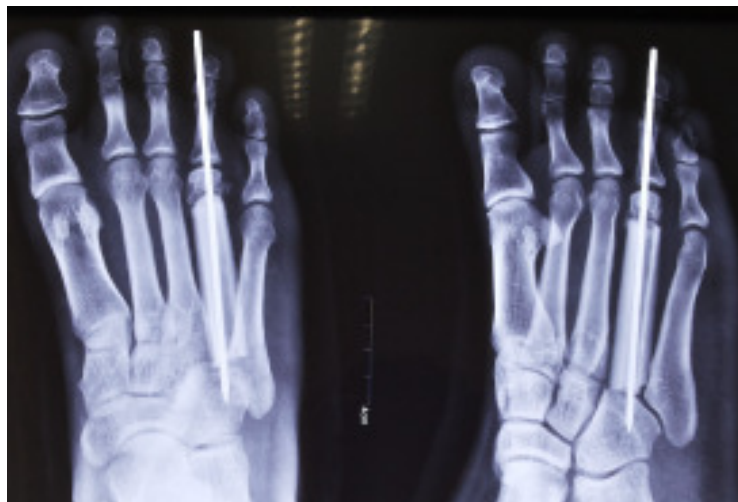

Fig. 5 : Reconstruction of the 4th metatarsal done by ipsilateral fibular graft.

DISCUSSION

Foreign bodies in the feet following puncture wounds are uncommon. Some of the foreign bodies reported in literature include glass, metallic objects, and organic materials. Glass, ceramic, and metallic foreign bodies are almost always identified on plain radiographs. Organic materials and plastics, on the other hand, are diagnostic challenges because they do not show up on plain radiographic films.¹ Migrated organic foreign bodies may be difficult to identify even on ultrasound and CT scans. The effects of plant thorn in soft and bony tissues include foreign body cyst, bursitis, tenosynovitis, synovitis, monoarthritis, and bone lesions that may mimic a tumor.²⁻⁴ The most frequently reported injuries are those to the hands, knees, and feet (metatarsal, cuneiform, cuboid, and phalangeal lesions), and these injuries may be intra-articular or limited to the soft tissues.^{1,5} Our foreign body (Pine leaf stick fragment from broomstick) survived in the body without any chemical degradation but caused a low-grade inflammation leading to chronic osteomyelitis of the 4th metatarsal although it was present dorsal to the metatarsal neck surrounded by fibrosis and inflammatory granulation tissue.

The median time from the injury to the detection of the osseous lesion is variable from some months to many years (4 months-20 years). This can lead to a clinically significant delay in making the correct diagnosis.^{1,3,5} If the foreign body is not removed immediately, or is not phagocytosed during the acute inflammatory reaction, it becomes encapsulated with fibrous tissue and forms a granuloma.² In our case the patient reported to us 2 years after penetration and the foreign body was swollen and intact being a pine wood stick from a broom.

The bone lesion that is induced by a thorn or a wood splinter usually appears to be a consequence of

infection resulting in osteolysis or periostitis or both.⁵ The other differential diagnosis for bony reaction to an unrecognised organic foreign body includes osteoid osteoma, chronic and acute osteomyelitis, tuberculosis granuloma, bone cyst, aneurysmal bone cyst, and cortical fibrous defect.^{2,3} The inflammatory reaction in our case was unique as the fragment was out of the bone and chronic osteomyelitis of the 4th metatarsal still developed.

Retained non-radiopaque foreign body inside soft tissue can be a cause of prolonged morbidity. Detection and localization is a difficult task with conventional radiography. Removal of foreign body relieves the patient from symptoms. We had to excise the whole metatarsal and reconstruct it as it was totally destroyed.

REFERENCES

1. E.J. Harris, "Retained hawthorn fragment in a child's foot complicated by infection: diagnosis and excision aided by localization with ultrasound," *Journal of Foot and Ankle Surgery*, vol. 49, no. 2, pp. 161-165, 2010.
2. E. Bouajina, L. Harzallah, M. Ghannouchi et al., "Foreign body granuloma due to unsuspected wooden splinter," *Joint Bone Spine*, vol. 73, no. 3, pp. 329-331, 2006.
3. A. Vega Curiel, M. Villaverde Romon, F. Carillo Lucia, M. Ruiz Del Portal Bermundo, and A. Carranza Bencano, "Injuries from palm tree thorn simulating tumoral or pseudotumoral bone lesions," *Acta Orthopaedica Belgica*, vol. 67, no. 3, pp. 279-282, 2001.
4. M. Barry, N. Maquillu, and C. Good, "The missed thorn," *Acta Orthopaedica Belgica*, vol. 58, no. 4, pp. 468-470, 1992.
5. H.R. Dur, A. Stabler, P. E. Müller, and H. J. Rehor, "Thorn induced pseudotumor of the metatarsal: a case report," *Journal of Bone and Joint Surgery*, vol. 83, no. 4, pp. 580-585, 2001.

ROLE OF AUGMENTATIVE NAILING IN PERI-IMPLANT FRACTURE IN A FAILED SUPRACONDYLAR FRACTURE FEMUR - A CASE REPORT

Saranghi J.*

Mohapatra N.C.**

ABSTRACT

Introduction: Supracondylar femur fractures occur most frequently either as high energy injuries in young men or low energy fractures in elderly women. Osteoporosis, bone loss, comminution multiply the challenges for an orthopedician to stabilize such fractures. One of the commoner complications of fixation of fractures in such bone is the occurrence of peri implant fractures with subsequent management requiring significant surgical acumen and judgment.

Case presentation: We report a case who sustained a supracondylar femur fracture, which was initially managed with a broad dynamic compression plate and screw assembly that eventually lead to non union due to mechanical failure. Then the patient was managed with removal of plate and screw assembly and treated by a locking compression plate with bone grafting. However the patient sustained a peri implant fracture during her post operative rehabilitation period. Using a minimally invasive method we removed few screws from the plate to negotiate an intramedullary implant and the rotational stability was achieved through the anterior to posterior locking bolt which was specifically designed for the purpose. The union proceeded uneventfully.

Conclusion: Use of such specifically designed intramedullary implants can be beneficial in such complicated situations.

Key words: Osteoporosis, Peri implant fracture, Stress riser, Supracondylar femur fracture, Locking plate.

INTRODUCTION

Supracondylar femur fractures occur most frequently either as high energy injuries in young men or low energy fractures in elderly women.¹ Osteoporosis, bone loss, comminution multiply the challenges for an orthopedician to stabilize such fractures.² Open reduction and internal fixation with a plate to these fractures usually involves soft tissue stripping resulting in devascularisation of the already weakened bone. Moreover stress riser phenomenon is a well known anticipated event when any fracture is stabilized with a rigid construct leaving an area of poor quality bone.^{3,4} So peri-implant fractures in such cases are more common. However for these type of fractures management guidelines are not still established. So we report a case where the supracondylar fracture in the osteoporotic bone was plated twice and sustained refractures at the interface. To avoid the problems of further devascularisation and extensive exposure and consequent complications we used specially designed intramedullary nail to augment fracture healing.

CASE PRESENTATION

A 65 year old female presented to our emergency

department with complains of pain around thigh and unable to walk unaided and shortening of involved limb around 5 cm. She had sustained a fracture of femur in the supracondylar region and the fracture was fixed with a broad dynamic compression plate (DCP) screw assembly elsewhere 1 year back. X rays revealed non union at the fracture site which was obviously a mechanical failure. So the plate assembly was removed and distal femur locking plate with bone graft was applied to stabilize the fracture at a private hospital. On the third post operative day patient presented to our emergency department with complain of pain around proximal thigh, shortening of involved limb around 3 cm and X ray showing peri-implant fracture proximally.

We had few options left like superimposed plating with a locking plate anteriorly, plate removal and intra medullary nailing, superimposed proximal femoral nail, illizarov fixation.⁵ We were planning for minimal invasive procedure. So based upon the best available evidence reamed nailing was planned. But the major issue was in application of distal locking bolt which super imposed the previous plate surface. Anticipating the difficulties in distal locking with an in situ plate the nail was designed with anterior posterior distal locking bolt hole.⁶ The

* Resident
** Asso. Prof.

Address for correspondence:
Dr Jitendra Sarangi
Department of Orthopaedics
SCB Medical College, Cuttack

ROLE OF AUGMENTATIVE NAILING IN PERI-IMPLANT FRACTURE IN A FAILED SUPRACONDYLAR FRACTURE FEMUR

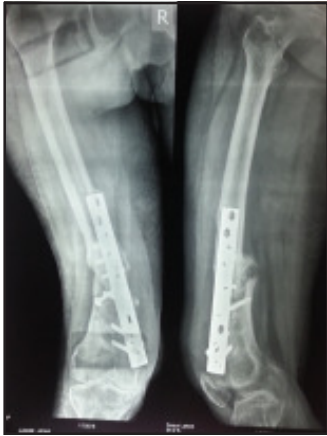

Fig. 1 : Preoperative X Ray showing non union

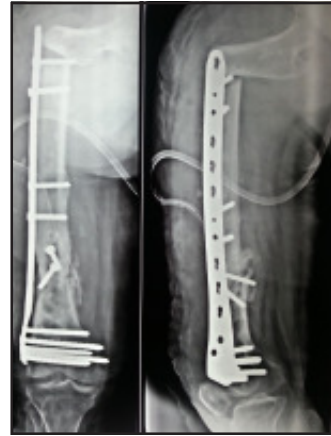

Fig. 2 : ORIF + Bonegraft At fracture site. The Fracture above plate has been missed

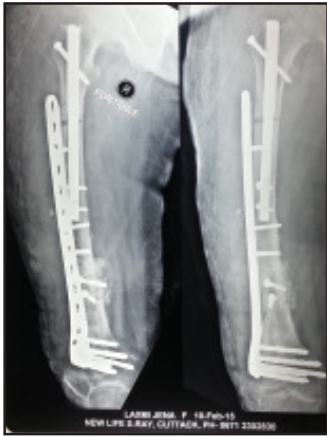

Fig. 3 : Post minimally invasive nailing




Fig. 4 : Xray after 3 months of surgery

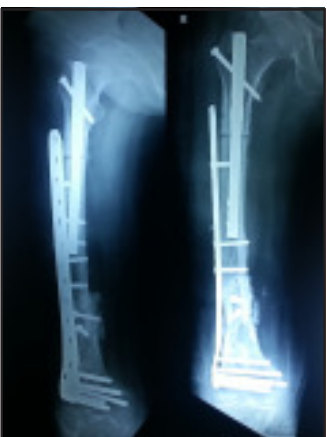

Fig. 5 : Xray after 3 months of followup

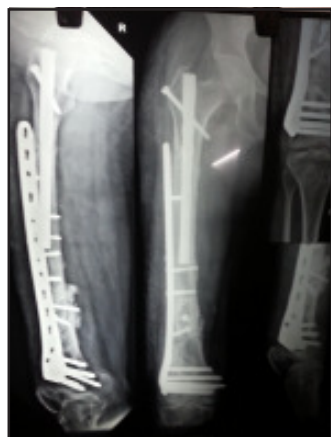

Fig. 6 : Xray Picture after union

screws in the plate were removed percutaneously under image intensifier control to ensure the patency of intramedullary canal leaving the plate in situ to avoid reexposure of the bone surface. The fracture was reduced and fixed with a reamed antegrade intramedullary nail. Under fluoroscopy control distal locking was done. No blood transfusion was used and the mean operating time was 60 minutes. The patient was advised range of motion exercises of the knee from 3rd post operative day. The follow up was done at six weeks interval and partial weight bearing with walker allowed. At a mean follow up of 12 weeks when the signs of healing were seen on the radiographs unaided weight bearing was allowed. The fracture united at 20 weeks with a mean range of motion of the ipsilateral Knee being 0 to 120 degrees. There were no complications associated with the procedure.

DISCUSSION

The aim of representing this case was to garner both in vivo and clinical evidence that intramedullary nails with anterior posterior locking hole provide improved fixation for peri-implant fracture in osteoporotic bone. The biomechanical evidence consistently documents that Plates act as stress shielding devices where the implant causes the creation of a stress riser at the end of the plate.⁷ This was the case with our patient whose initial fracture united by the plating procedures but a new fracture was created at the stress riser. This problem is especially more pronounced in the osteoporotic bone. Intramedullary nails provide stronger anchorage with better resistance to failure than conventional plates and these are more load sharing than load bearing.⁸

Our patient was particularly difficult to manage in view of the fact that she had undergone surgery for the same limb for two occasions with plating technique and long term immobilization increased the morbidity. Removing the implant and using a longer plate would mean denudation and devitalisation besides causing large amount of blood loss. In our case, it was difficult to envisage a modification in the initial surgery. Retrospective analysis indicated that use of a retrograde nail at the outset might have prevented the peri implant fracture.

The advantages of our technique are avoidance of reexposure of the fracture site, closed reamed nailing which resulted early mobilization of the patient with good

functional outcome. The major disadvantage of this technique was anterior to posterior screw might disrupt the quadriceps mechanism, but such minimally invasive technique rarely hampered the quadriceps function in our case.⁶

CONCLUSION

Both intra medullary nailing and plating may be adequate treatment options for peri-implant fractures. However IM nailing provides favorable IM stability, promotes formation of circular and stable callus, and can be successfully implanted in peri-implant fractures of the lower extremity with plate in situ. However, this requires precise preoperative planning and advanced surgical experience to reduce the risk of revision surgery. Clinical outcome may largely depend on surgical technique and rather than on the choice of implant. Multicenter studies with high numbers of patients are required to draw useful conclusions.

REFERENCES

1. Streubel PN, Ricci WM, Wong A, Gardner MJ: Mortality After Distal Femur Fractures in Elderly Patients. *CORR* 2011;469:1188-96.
2. Raisz LG: Pathogenesis of osteoporosis: concepts, conflicts, and prospects. *J Clin Invest* 2005;115:3318-25.
3. Kawoosa AA, Dhar SA, Butt MF, Dar GN and Mir MR: The role of composite technique in managing peri implant re-fractures in a case with supracondylar fracture of the femur: a case report. *Cases Journal* 2009;2:8174.
4. Egol KA, Kubiak EN, Fulkerson E, Kummer FJ, Koval KJ: Biomechanics of Locked Plates and Screws. *J Orthop Trauma* 2004;18: 488-93.
5. Cove JA, Lhowe DW, Jupiter JB et al: The management of femoral diaphyseal non-unions. *J Orthop Trauma* 1997;11: 513-20.
6. Zehnder S, Bledsoe JG, Puryor A. The effects of screw orientation in severely osteoporotic bone: a comparison with locked plating. *Clin Biomech* 2009;24:589-94.
7. Snow M, Thompson G, Turner PG. A mechanical comparison of the locking compression plate (LCP) and the low contact-dynamic compression plate (DCP) in an osteoporotic bone model. *J Orthop Trauma*. 2008; 22:21-5.
8. Park J, Kim SG, Yoon HK et al. The treatment of nonisthmal femoral shaft non-unions with im nail exchange versus augmentation plating. *J Orthop Trauma*. 2010;24:89-94.

CLINICAL, FUNCTIONAL AND RADIOLOGICAL OUTCOME FOLLOWING HERBERT SCREW FIXATION OF CAPITELLUM FRACTURE

Bhatia C.*

Goel N.**

Goel R.***

Thalanki S.****

ABSTRACT

Introduction: Capitellum fractures account for 1% of elbow fractures. As the complex nature of capitellum fractures has become better appreciated, treatment options have evolved from closed reduction, immobilization and fragment excision to a preference for open reduction and internal fixation with Kirschner wires, cannulated cancellous screws and Herbert screws. **Materials and Methods:** Twenty patients with displaced fractures of the humeral capitellum were treated by open reduction and internal fixation of the capitellum fractures with Herbert screws. The mean follow-up period was 14 months (range 12-22 months) and the mean age was 35 years (range 20-54 years). All patients were evaluated according to the Mayo elbow performance score.

Results: Overall, in sixteen patients results were found to be excellent and that of four were good. All patients were satisfied with the operative outcome and had a stable pain-free elbow with good range of motion at follow-up without any avascular necrosis or arthritic changes. The mean range of motion at elbow was 1310(121 to 1400). They all had full pronation and supination and had good stability. None of the patients had residual pain.

Conclusion: Treatment of capitellum fractures by Herbert screw leads to minimal articular damage and rigid fixation with solid union and excellent compression as well as early mobilization. Encountering a free capitellar fragment and nonunion should not discourage the use of internal fixation, as avascular necrosis is less likely to occur with good fixation and early mobilization.

Key words:Capitellum fracture, Herbert screw.

INTRODUCTION

Capitellum fractures is a rare injury.^{1,2,3} Isolated capitellum fractures accounts for 1% of elbow fractures and 6% of distal humerus fractures.^{2,3} They fall in type B3 category of AO/OTA classification of distal humerus fractures.⁴ Capitellum fractures are generally coronal shear fractures. Most common mechanism of injury is fall on outstretched hand.⁵ When the person falls direct axial compression transmitted to the capitellum through the radial head that provides a shearing and/or compressive load to the capitellum and occasionally to the trochlea causing the fracture.⁶

Treatment options for capitellum fractures have evolved from closed reduction and immobilization in cast to excision of the fractured fragment to open reduction and internal fixation.

Displaced fractures invariably lead to poor outcome if left untreated. The displaced fragment can migrate superiorly and unite with anterior humerus and cause mechanical block to elbow flexion by obstructing the

radial and/or coronoid fossa.⁷ An untreated displaced capitellar fragment may also undergo changes resulting from bony absorption to bony proliferation resulting in arthritic degeneration of the elbow joint thus limiting range of motion.^{8,9,10} Excision of the fragment^{9,11} has also been advocated as a treatment but remaining raw bone surfaces after excision predispose the elbow to capsular adhesions resulting in restricted elbow mobility.⁷

Internal fixation has been tried with Kirschner wires (K-wires), cannulated screws and Herbert screws.^{1,2} Given the rarity of these fractures, it has been difficult to formulate a universally accepted method of fixation. Headless screws provide distinct advantages over other modes of fixation that they provide stable fixation with least damage to the articular surface. Moreover, early mobilization can be started and the hardware need not be removed later.⁸

The purpose of this study was to perform an evaluation of clinical, radiological and functional outcome of 20 cases of capitellum fractures treated using Herbert screws.

* Resident
** Asst. Prof.
*** Professor
**** Resident

Address for correspondence:
Dr. Chirag Bhatia, Department of Orthopaedics,
Govt. Medical College, Kota, Rajasthan, India.
E-mail: drbhatiachirag@gmail.com

MATERIALS AND METHODS

Twenty patients of capitellum fractures from ages 20 yrs to 54 yrs were treated by open reduction and internal fixation with Herbert screws from the period January 2011 to September 2014. Standard antero-posterior and lateral radiographs of the injured elbow were obtained to evaluate the fracture. CT scans were also obtained to evaluate comminuted fractures. The average period of follow up was 14 months.

Injuries less than 6 weeks old, all closed fractures and gustillo type I open fractures were included in the study. All undisplaced fractures, severely comminuted fractures, fractures with metaphyseal or diaphyseal extension, fractures with associated ligament injuries and gustillo type II & III open fractures were excluded from the study.

All fractures were classified using Bryan and Morrey classification with McKee et al modification (Figure 1).

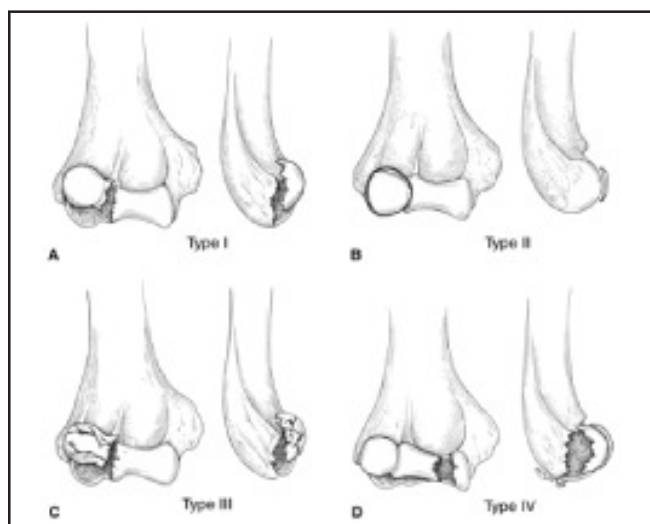


Fig. 1 : Bryan and Morrey classification. (Type IV is McKee et al addition to this classification).

All cases operated under regional/ general anesthesia with tourniquet applied. Extensile lateral approach to the elbow using Kocher's interval was used to expose the fracture site. After obtaining reduction Herbert screws were inserted in antero-posterior direction. Post-operatively passive mobilization of elbow starts 3rd post op day and active mobilization after suture removal (10-12 days). Elbow was supported in a brace in between exercises which was discarded after 6-8 weeks. Patients were evaluated post-operatively at 4 weeks, 8 weeks, 3months, 6 months, 1 year. All patients were followed for minimum 12 months for clinical and

radiological assessment. Final functional outcomes were evaluated using Mayo elbow performance index (MEPI) (Table 1).

Table 1
Mayo elbow performance index

Function	Points	Definition	Points
Pain	45	None	45
		Mild	30
		Moderate	15
		Severe	0
		Extremity	0
Motion	20	Arc > 100°	20
		Arc 50-100°	15
		Arc < 50°	5
Stability	10	Stable	10
		Moderate instability	5
		Gross instability	0
		Comb hair	5
Function	25	Feed	5
		Hygiene	5
		Wear shirt	5
		Wear shoes	5
			5

Total score = 100, Excellent Result = >90, Good Result= 75-89, Fair Result = 60-74, Poor Result = <60.

RESULTS

Out of 20 patients in our study 13 were females and 7 males. Mean age was 35 yrs. Non-dominant extremity was involved in 12 patients. Eighteen cases were of closed fractures and 2 were gustillo type 1 open fractures. Fourteen patients had presented within 1 week of injury. Four patients had associated radial head fracture, 3 had distal end radius fractures and 2 had scaphoid fracture all on the ipsilateral side. These associated injuries were managed accordingly.

According to Bryan and Morrey classification Type I fractures were most commonly encountered. Out of the 20 cases treated 11 were type I fractures, 4 were type II, 1 was type III and 4 were type IV fractures (Table 2).

Table 2
Types of fractures encountered

Bryan & Morrey type	No. of cases	Percentage
Type 1	11	55%
Type 2	4	20%
Type 3	1	5%
Type 4	4	20%

As per Mayo elbow performance index 16 out of 20 cases had excellent functional outcome and 4 had good outcome (Figure 2). Mean score as per the index was 94. Of the 16 excellent results 8 belonged to Bryan and Morrey type I category, 4 to type II and 4 to type III category. Out of 4 good good results 3 belonged to type I and 1 to type III category (Figure 3).

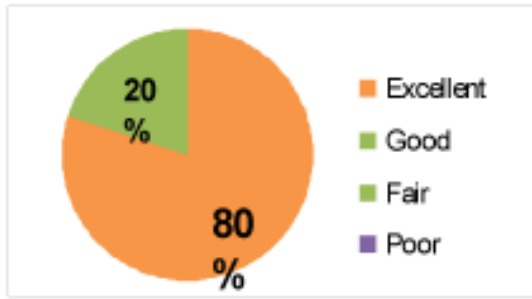


Fig. 2 : Overall functional results as per MEPI

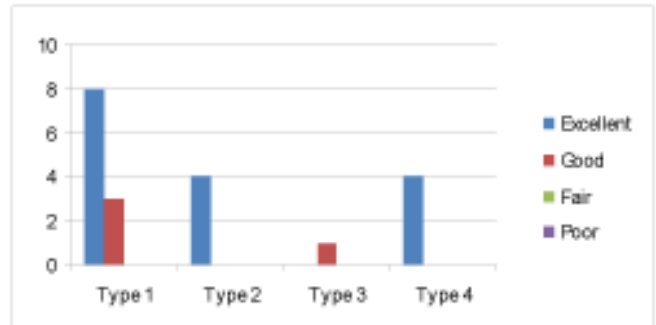


Fig. 3 : Final outcomes of different fracture types.

On radiological evaluation all fractures had healed well. Mean time of union was 14 weeks. 2 patients had grade I arthritic changes (assessed using Broberg and Morrey system) but were doing well functionally on the last follow up. No evidence of avascular necrosis of the fractured fragment in any of the cases. No case had any heterotopic ossification.

Mean range of motion at the elbow in flexion/extension was 131(121 to 1400). Mean loss of extension

was 50(0 to 100). All patients had full supination and pronation. None of the patients complained of any residual pain and all had good stability at the elbow.

ILLUSTRATIVE CASE REPORT

34 year old female with fracture capitellum (Type 1) right side due to fall on outstretched hand treated by ORIF with single Herbert screw (Fig 4 & Fig 5). Range of motion at final follow up was 0 - 1400. Final outcome was excellent (Fig 6).

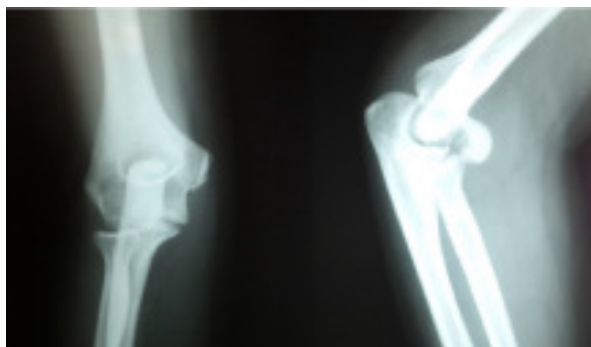

Fig. 4 : Preoperative radiographs.

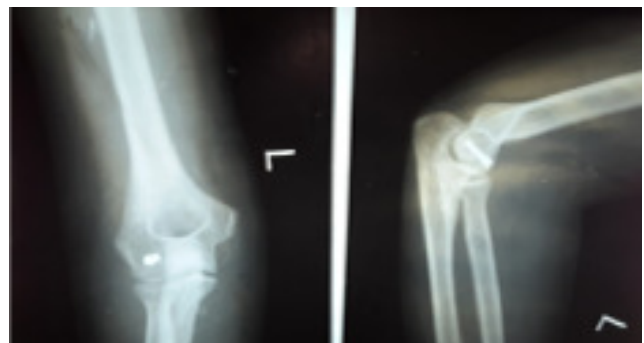

Fig. 5 : Radiographs at final follow up.

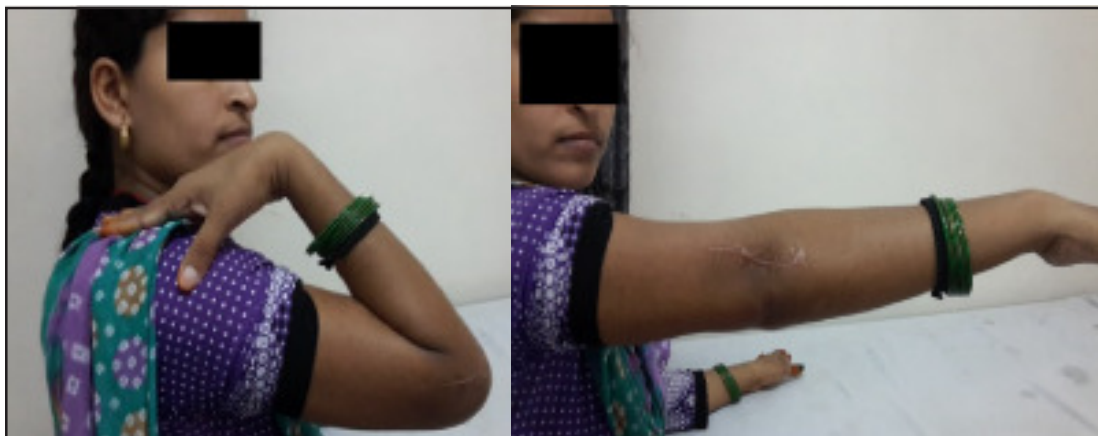

Fig. 6 : Final outcome -Excellent

DISCUSSION

A variety of treatment methods for capitellum fractures have been described in literature. These include closed reduction followed by immobilization in a cast, excision of the fractured fragment, open reduction and internal fixation with K-wires, Cannulated screws and Herbert screws. Open reduction and internal fixation is the preferred method of treatment now days.

Open reduction and internal fixation is a suitable method for maintaining joint congruity while allowing for early mobilization. Kirschner wires and AO compression screws have been used with varying degrees of success. Kirschner wires do not offer compression at the fracture site and require subsequent removal.⁸ Fixation with compression screws irritates the cartilage of the radial head, as the metal head protrudes from the articular surface. Cannulated screws introduced posteriorly through the humerus into the capitellum avoid this problem.¹² However, if the osteochondral fragment is small the screw may split it.

Accurate reduction and stable fixation of the fracture and early postoperative mobilization has been reported to provide good results.^{6,8,13,14} Herbert screws allow rigid fixation at the fracture site, provide fracture site compression through variable thread pitch design and need not be removed later.⁸ These screws can be used both in antero-posterior and postero-anterior directions.^{6,8,13,14,15} In our study screws were placed in an antero-posterior direction in all the cases.

With a look at the previous studies we can say that our results were quite comparable. Ruchelsman et al treated 16 patients of capitellum fractures with Herbert screws giving excellent results in 9 patients, good in 6 and fair in 1 as per MEPI.² Ring et al treated 21 patients with headless screws giving excellent results in 4, good in 12 and fair in 5 patients as per MEPI.¹⁶ Mighellet all treated 18 patients using headless screws and used Broberg Morrey score as the method of assessment. The results were excellent in 12, good in 5 and poor in 1 patient.¹ Dubberley et al treated 28 patients using cannulated cancellous screws with mean MEPI score of 91 in which 9 cases were complicated by osteoarthritis.¹⁷ Osteoarthritis was seen in very few cases in studies using Headless screws for fixation.

Avascular necrosis is uncommon after open reduction and internal fixation of capitellum fractures.^{18,19} The reported incidence of avascular necrosis is 0-30%.⁸ No patient in our series had avascular necrosis. Mehdian et al. recommended that encountering a free capitellar fragment should not discourage the use of internal fixation.²⁰ Literature suggests that if osteonecrosis does

not occur within one year, it is unlikely to occur.¹⁶

CONCLUSION:

To conclude we recommend Open reduction and internal fixation with Herbert screws as the preferred method of treatment of capitellum fractures as headless screws provide stable fixation with minimal damage to the articular surface, allowing early mobilization and give solid union with very good clinical and functional outcome.

REFERENCES

1. Mighell M, Virani NA, Shannon R, Jr ELE, Badman BL, Keatingf CJ. Large coronal shear fractures of the capitellum and trochlea treated with headless compression screws. *J Shoulder Elbow Surg.* 2010;19:38-45.
2. Ruchelsman DE, Tejwani NC, Kwon YW EK. Open reduction and internal fixation of capitellar fractures with headless screws. *J*
3. Bryan RS, Morrey BF. Fractures of the distal humerus. In: Morrey BF, editor. *The elbow and its disorders.* Philadelphia, PA: WB Saunders; 1985. p. 302-39.
4. Mueller ME, Nazarian S, Koch P, Schatzker J. *The comprehensive classification of fractures of long bones.* New York: Springer; 1990.
5. Harrington JP, McKee MD. Coronal shear fractures of the capitellum and trochlea. *Tech Shoulder Elbow Surg* 2000; 1:240-6.
6. Sano S, Rokkaku T, Saito S, Tokunaga S, Abe Y, Moriya H. Herbert screw fixation of capitellar fractures. *J Shoulder Elbow Surg* 2005;14: 307-11.
7. Guitton TG, Doornberg JN, Raaymakers EL, Ring D, Kloen P. Fractures of the capitellum and trochlea. *J Bone Joint Surg Am* 2009;91:390-7.
8. Mahirogullari M, Kiral A, Solakoglu C, Pehlivan O, Akmaz I, Rodop O. Treatment of fractures of the humeral capitellum using Herbert screws. *J Hand Surg (Br Eur Vol)*2006;31:320-325. doi: 10.1016/j.jhsb.2006.02.002.
9. Alvarez E, Patel MR, Nimberg G, Pearlman HS. Fracture of the capitellumhumeri. *J Bone Joint Surg Am.* 1975; 57:1093-1096.
10. Dushuttle RP, Coyle MP, Zawadsky JP, Bloom H. Fractures of the capitellum. *J Trauma.*1985; 25:317-321. doi: 10.1097/00005373-198504000-00006.
11. Wilson JN. Injuries of the elbow. In: Watson-Jones R, editor. *Fractures and joint injuries.* Edinburgh: Churchill Livingstone; 1982. pp. 587-590.
12. Stamatis E, Paxinos O. The treatment and functional outcome of type IV coronal shear fractures of the distal humerus: a retrospective review of five cases. *J Orthop Trauma.*2003;17:279-284. doi: 10.1097/00005131-200304000-00006.

CLINICAL, FUNCTIONAL AND RADIOLOGICAL OUTCOME FOLLOWING HERBERT SCREW FIXATION OF CAPITELLUM

13. Silveri CP, Corso SJ, Roofeh J. Herbert screw fixation of a capitellum fracture: a case report and review. *ClinOrthop*. 1994; 300:123-126.
14. Simpson LA, Richards RR. Internal fixation of capitellar fractures using Herbert screws: a case report. *ClinOrthop*. 1986;209:166-168
15. Liberman N, Katz T, Howard CB, Nyska M. Fixation of capitellar fractures with the Herbert screw. *Arch Orthop Trauma Surg*. 1991; 110:155-157. doi: 10.1007/BF00395799.
16. Ring D, Jupiter JB, Gulotta L. Articular fractures of the distal part of the humerus. *J Bone Joint Surg Am* 2003;85-A:232-8.
17. Dubberley JH, Faber KJ, Macdermid JC, Patterson SD, King GJ. Outcome after open reduction and internal fixation of capitellar and trochlear fractures. *J Bone Joint Surg Am* 2006;88:46-54.
18. McKee MD, Jupiter JB, Bamberger HB. Coronal shear fractures of the distal end of the humerus. *J Bone Joint Surg [Am]* 1996;78:49-54.
19. Bryan RS, Morrey BF. Fractures of the distal humerus. In: Morrey BF, editor. *The elbow and its disorders*. Saunders: Philadelphia; 1985. pp. 325-333.
20. Mehdian H, McKee MD. Fractures of capitellum and trochlea. *OrthopClin North Am*.2000; 31:115-127. doi: 10.1016/S0030-5898(05)70132-2.

HEREDITARY MULTIPLE EXOSTOSIS : A CASE REPORT

Verma S.*

Deshwar G.*

Sharma B.**

Pal C.P.***

ABSTRACT

Introduction: Hereditary Multiple Exostosis (HME) is a rare autosomal dominant disorder affecting the endochondral skeleton during growth¹. It is a cartilage capped bony projection found primarily at the juxta-epiphyseal regions of the most rapidly growing ends of bone. It is the most common bone tumour seen in children^{3,4}. It is considered a hamartoma and as such stops growing at the end of the growth of the affected bones. Mutations in three genes (EXT 1, EXT 2 and EXT 3) have been implicated in the aetio-pathogenesis. In the absence of pain and deformities, masterly inactivity is the rule.

Case report: A 20 year old girl, presented multiple swellings since birth. They were multiple and on the right upper arm, both wrists and both lower limbs. Initially, they were small sized (0.5cmx1cm) but progressively increased in size over time. No history of pain, change in skin colour or ulceration. There is family history of similar swelling. Her brother and mother also have multiple swellings.

Conclusion: Hereditary Multiple Exostosis is a rare disease. Sporadic mutations still occurs in patients with no family history. The treatment of non-complicated HME is watchful waiting, with the aim of intervening surgically when complications arise.

Keywords: Hereditary multiple exostosis, Autosomal Dominant, sporadic mutation.

INTRODUCTION

Hereditary Multiple Exostosis (HME) is a rare autosomal dominant disorder affecting the endochondral skeleton during growth.¹ 10-20% can arise spontaneously. It is a cartilage capped bony projection found primarily at the juxta-epiphyseal regions of the most rapidly growing ends of bone.

The long bones of the legs, arms, fingers, toes and shoulder blades are commonly affected. Face and skull are severally unaffected. Exostosis grow as the child grows. It is the most common bone tumour seen in children.^{3,4}

It is considered a hamartoma and as such stops growing at the end of the growth of the affected bones. It is estimated to occur in about 1 in 50,000 people. It causes asymmetrical retardation of longitudinal bone growth with subsequent deformity and discrepancy in limb-length (very common). Significant inequality of more than or equal to 2cm has been reported. Malignant transformation is in order of 5% of all cases.⁵ The femur is twice affected as the tibia.⁶

Mutations in three genes (EXT 1, EXT 2 and EXT 3) have been implicated in the aetio-pathogenesis.

These lesions have the tendency to cause mechanical interference with normal function of the soft tissues passing over them.

The pressure of the exostosis causes irritation and occasional damage to nerves, arteries and muscles, hence, the presence of pain. A second clinical setting, presents as multiple lumps, pain or deformity, while the third setting will present with multiple lumps, pain, and deformities. Management will depend on the stage of presentation.

In the absence of pain and deformities, masterly inactivity is the rule. However, surgical intervention is paramount in the presence of deforming complications.

CASE REPORT

A 20 year old girl, presented at the out-patient department of orthopaedics S.N. Medical College, Agra with history of multiple swellings since birth. The Swellings were noticed by the parents. They were multiple and on the right upper arm, both wrists and both lower limbs. Initially, they were small sized (0.5cm x 1cm) but progressively increased in size over time. No history of pain, change in skin colour or ulceration. No history of trauma. No history of weight loss, headaches, anorexia,

* Senior Resident
** Lecturer
*** Head of Department

Address for correspondence:
Dr. C.P. Pal, M.S. (Ortho.)
Assistant Professor & Head of department
Department of orthopaedics
S.N. Medical College, Agra
E-mail-drcportho@gmail.com

HEREDITARY MULTIPLE EXOSTOSIS : A CASE REPORT

bone pain, jaundice, cough or breathlessness, abdominal swelling or any other constitutional symptom. Pregnancy was carried to term. Perinatal period was uneventful. There is family history of similar swelling. Her brother and mother also have multiple swellings.

General examination was unremarkable. On examination of the musculo-skeletal system, there were non-tender hard swelling over the right upper arm. There were also multiple non-tender hard swellings on the distal end of both forearms. On both lower limbs, there were similar bony hard swellings on the medial and lateral surfaces of the distal third of both thighs and medial side of the proximal and distal third of both legs. However, the lesion on the right upper arm is big. There were no limb length discrepancies.

There was no change in colour of overlying or surrounding skin. No differential warmth or lymphadenopathy. No loss of distal neurovascular

function. A diagnosis of hereditary multiple exostosis was made.

The result of haemoglobin estimation, genotype, erythrocyte sedimentation rate, and full blood count were within normal ranges for his age.

Radiograph of both thigh with hip and knee (Figure 1) showed bony out-growths in the proximal femur, distal femoral metaphysis and deformed neck of femur. Radiograph of both leg with knee and ankle (Figure 2) showed outgrowth from proximal and distal tibial & fibula metaphysis, growing away from the physis. In the upper limbs, radiograph of the right shoulder (Figure 3) and both wrists (Figure 4) revealed multiple bony outgrowths. Biopsy of one of the lesions showed Osteochondroma on histopathology.

Parents and patient were counselled on outcome and natural history of the ailment. He is presently on three monthly checks- up visits.

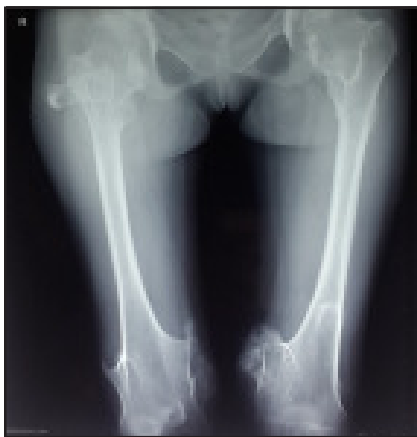

Fig. 1 : X-ray Bilateral thigh with hip and knee.

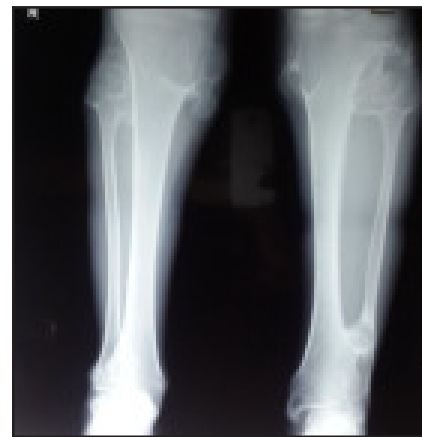

Fig. 2 : X-ray Bilateral leg with knee and ankle.

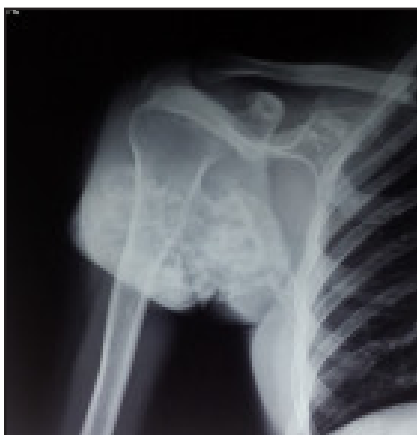

Fig. 3 : X-ray right shoulder with arm

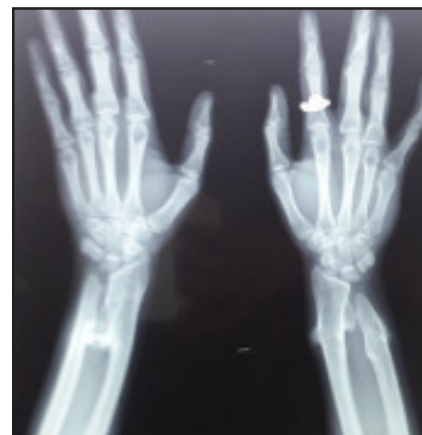

Fig. 4 : X-ray bilateral wrist with hand and forearm

DISCUSSION

Hereditary Multiple Exostosis is an autosomal dominant hereditary disorder. 10-20% arises spontaneously. There are mutations in three genes: EXT 1 which maps to chromosome 8q24. EXT 2 which maps to 11p13, and EXT 3 maps to short arm of chromosome 19. HME affects both sexes equally.⁷

Mutations in this genes cause synthesis of truncated EXT protein with abnormal function. EXT protein is important in Heparan Sulfate synthesis. It is thought that normal chondrocyte proliferation and differentiation may be affected, leading to abnormal bony growth. Pre-implantation genetic testing and prenatal diagnosis are available for new couples. HME has 95% penetrance. Expressivity is variable. In a patient with a negative family history of the disease, the patient may be the first to clinically express the trait, this may be due to sporadic mutation.

Exostosis are initially recognised and diagnosed in the first decade of life in over 80% of individuals with HME. Tibia and scapula are often most noticeable locations.⁸ Clinical and radiological findings are usually diagnostic. Clinical features will depend on time of presentation. Pathology will depend on site, size and extent of physeal involvement.

Multiple bony swellings of the proximal humerus and distal radius and ulnar, with swellings of the distal femur and proximal tibia are the hallmark of presentation. The scapula and pelvis can be involved.⁹ Late presentations are usually accompanied by complications such as pain and deformities. Peripheral nerve compression symptoms can occur in up to 22.6% of patients. Peroneal Neuropathy in children is an example.¹⁰ Malignant changes do occur with transformation from osteochondroma to chondrosarcoma. The incidence of malignant transformation ranges from 0.5-2.5%.¹¹

In our patient, the presentation is since birth. Symptoms were mainly multiple swellings on the proximal humerus, distal radius, distal femur and proximal tibia.

As collaborated by other works^{6,7,9}, early presentations are not usually associated with pain and

deformity. Hence, he has no pain or deformity. There was no asymmetrical growth retardation or limb length discrepancy.

CONCLUSION

Hereditary Multiple Exostosis is a rare disease. Sporadic mutations still occurs in patients with no family history. The treatment of non-complicated HME is watchful waiting, with the aim of intervening surgically when complications arise.

REFERENCES

1. Venuta A, Laudizi L, Forese S, et al. The multiple exostoses syndrome: 3 cases in one family. *Paediatr Med Chir.* 1994; 16: 403-4.
2. Peterson HA. Multiple hereditary osteochondroma. *Clinical Orthopaedics.* 1989; 239: 222-230.
3. Dahlin DC, Unni KK. *Bone Tumors: General aspects and data on 11, 087 cases.* 5th Ed. Philadelphia: Lippincott-Raven; 1996. P. 11-23.
4. Schmale G.A, Conrad EU, Raskind WH. The natural history of HME. *J Bone Joint Surg.* 1994; 76: 986- 992.
5. Pannier S, Legeai - Mallet L. Hereditary Multiple Exostoses and Enchondromatosis. *Best Practice& Research Clinical Rheumatology.* 2008; 22: 45-54.
6. Henneken RCM. Hereditary Multiple Exostoses. *Journal of Medical Genetics.* 1991; 28: 262-266.
7. Wickland CL, Pauli RM, Johnston D, Hecht JT. Natural History study of Hereditary Multiple Exostoses. *AM J Med Genetics.* 1995; 55: 43-46.
8. Stieber JR, Pierz KA, Dormans JP. Hereditary Multiple Exostoses: A current Understanding of clinical and genetic advances. *Clinical Orthopaedics and Related Research.* 2001; 14: 39-48.
9. Cordelia JM, Dormans JP, Drummend DS, Davidson RS, Duhainie C, Sutton I. Proximal fibula osteochondroma with associated Peroneal nerve palsy: A review of six cases. *Journal of Paediatric Orthopaedics.* 1995; 15: 574-577.
10. Shapiro F, Simon S, Glimcher MJ. Hereditary Multiple Exostoses. *Journal of Bone Joint Surgery.* 1979; 61: 815-824.
11. Garrison RC, Unni KK, Mcleod RA, Pritchard DJ, Dahlin DC. Chondrosarcoma arising in osteochondroma. *Cancer.* 1982; 49: 1890-1897.

A COMPARATIVE STUDY OF DIFFERENT TREATMENT MODALITIES OF LUMBAR CANAL STENOSIS

Pal C.P.*
Dinkar K.S.****

Srivastav D.C.**
Mittal V.****

Singh P.***
Deshwar G.*****

ABSTRACT

Purpose: Low back pain is a common burning and disabling condition. Lumbar canal stenosis may be defined as narrowing of osteoligamentous vertebral canal and /or intervertebral foramina, causing compression of thecal sac and /or caudal roots. The present study was undertaken to evaluate the outcome of the management of lumbar canal stenosis by conservative treatment, by epidural steroid and by surgical treatment.

Method: During this period, 53 (44 male and 9 female) patients of degenerative lumbar canal stenosis were evaluated. Majority of the patients were between 40 to 60 years of age (45 cases). All the patients had symptoms for more than 3 months duration at presentation. Out of 53 patients 18 patients were treated surgically, 10 by epidural steroid, and 25 patients were managed conservatively. MRI was done preoperatively to know the cause and level of stenosis.

Results: Preoperatively, 72% of patients presented with continuous severe low backache, 25% with occasional severe low backache, and 3 % presented with occasional mild low backache. Three months postoperatively, 62.5% patients had no back pain and 37.5% had occasional mild low back pain. No patient had occasional severe or continuous severe low back pain. Intermittant claudication was present in 48% cases before operation which was reduced to only 8 %. In 68% cases had sciatic pain before operation which was reduced to 4% after operation. 96.87% patients had no leg pain. All patients had preoperative claudication distance less than 100 m, but 93.75% patients had normal gait with walking distance more than 500 m and no claudication symptoms postoperatively.

Conclusion: The results of patients treated by conservative means and by epidural steroid did not give satisfactory results. Results of these three categories were assessed by Oswestry disability index. According to this index best outcome was amongst surgical treatment. However treatment by all modalities showed improvement.

INTRODUCTION

Low back pain is a common burning & disabling condition. Despite its frequency, back ache is not a dramatic disease but is a problem because of severity, persistence of pain, resultant disability and apprehension about future. Lumbar canal stenosis may be defined as narrowing of osteoligamentous vertebral canal and /or intervertebral foramina, causing compression of thecal sac and /or caudal roots. Narrowing may affect the whole canal or part of it. Bone or soft tissue can cause lumbar canal stenosis and narrowing can involve the bony canal or the dural sac or both. The compression of these nerve roots can be asymptomatic, but it can also become

symptomatic, resulting in weakness, reflex alterations, gait disturbances, bowel or bladder dysfunction, motor and sensory changes, radicular pain or atypical leg pain and neurogenic claudication. The anatomic presence of spinal stenosis is confirmed radiologically with computerized tomography (CT), myelography, or magnetic resonance (MR) imaging. The correlation of clinical symptoms with radiographic imaging is necessary to make the clinical diagnosis of lumbar spinal stenosis. Spinal stenosis can be classified into congenital/developmental and degenerative types which have been described by Arnoldi. Degenerative types are most commonly seen in males from 3rd to 5th segments of lumbar spine. Structures responsible for the stenosis

* HOD, Dept. of Orthopaedics,
S.N. Medical College Agra
** Professor and Head, Department of Orthopaedics
M.L.N Medical College, Allahabad, India
*** Asst. Prof., Department of Orthopaedics,
U.P Rural Institute of Medical Sciences & Research, Saifai
**** Lecturer, Department of Orthopaedics,
S.N. Medical College, Agra, India
***** Senior Resident, Dept. Of Orthopaedics,
S.N. Medical College Agra

Address for correspondence:
Dr. C.P. Pal, M.S. (Ortho.)
Assistant Professor & Head of department
Department of orthopaedics
S.N.Medical College, Agra
E-mail-drcportho@gmail.com

include zygapophyseal joint, ligamentum flavum, intervertebral disc, epidural venous structures, lamina and pedicles. Degeneration of these structures causes encroachment on the spinal canal both directly and as a result of narrowing of the disc spaces. The present study was undertaken to evaluate the outcome of the management of lumbar canal stenosis by conservative treatment, by epidural steroid and by surgical treatment.

MATERIAL AND METHOD

This prospective study was conducted in M.L.N Medical College, Allahabad. Cases were selected on the basis of thorough history and clinical examination. All the patients with low backache and intermittent claudication were analyzed. Apart from this, anteroposterior diameter of the canal was measured on the lateral radiograph from the middle of the posterior border of the vertebral body to the base of the opposing spinous process recognized by tracing forwards its inferior margin a distance marked 'B'. At the same level the interpedicular distance in the anteroposterior radiograph marked 'A' and then multiplying these two values together to get a product 'AB'. This product then compared as a ratio with the product of the anteroposterior and transverse diameter of the middle of the adjacent vertebral body marked 'D' and 'C' respectively, so that AB is related to 'CD' to get the Canal Body ratio at that level. This ratio was calculated for each lumbar vertebrae from plain radiograph of each patient to determine the canal stenosis AB/CD (John and Thompson index, 1968).

Patients not responding to conservative treatment and in whom surgery contemplated were subjected to MRI evaluation. Axial T1 weighted images were done and cross sectional area at the stenotic levels were determined. The dural sac was outlined and then cross sectional area measured. The reference values of the cross sectional areas of the dural sac were taken as follows

- Normal range - $180 \pm 50 \text{mm}^2$
- Relative stenosis - $100 - 70 \text{mm}^2$
- Absolute stenosis - $< 70 \text{mm}^2$

These values were then correlated with the neurological deficit of the patient.

Treatment protocols

Conservative treatment

Conservative treatment was given by bed rest on hard surface, lumbar traction, analgesics, muscle relaxants, methycobalmine and pregabalin and exercise after subsidence of pain. The amount of weight in traction

was 25% of the body weight and foot end should be raised by 15 degree with the help of wooden blocks,

Epidural steroid injection

Patients were treated by epidural injection of methylpredisolone and 0.625% sensoricaine through lumbar route. Under local anaesthesia the needle was usually inserted 5 cm beneath the skin. After confirming no csf coming out 5 cm air introduced into the space. It must go without resistance and there should not be any resistance of the piston of syringe.

Surgical treatment

Patients not responding to conservative treatment for approximately 3-4 weeks were considered for decompressive surgery. During this period, 53 (44 male and 9 female) patients of degenerative lumbar canal stenosis were evaluated. Majority of the patients were between 40 to 60 years of age (45 cases). Patients with primary bony canal stenosis, traumatic lumbar canal stenosis, stenosis due to tumors and infection, and patients not medically fit for surgery due to comorbidities were excluded from the study.

In 20 patients the presenting complaint was low backache with radicular pain while 18 patients had localized backache, 5 patients had paresthesia and 7 patients had low backache with neurological claudication. Out of 53 patients 18 patients were treated surgically, 10 by epidural steroid, and 25 patients were managed conservatively. MRI was done preoperatively to know the cause and level of stenosis. All cases were initially treated by conservative treatment by nonsteroidal antiinflammatory drugs muscle relaxants, heat therapy. Lumbar traction was given in patients which have radicular pain. After relief of pain and spasm, strengthening exercise were allowed. In 10 patients epidural steroids were given. Patients not responding to conservative treatment for approximately 3-4 weeks were considered for decompressive surgery.

Laminectomy with decompression was done in all cases. Discectomy was done in all cases with a soft bulging disc intraoperatively. Instrumented stabilization was done in all cases with preoperative instability and when laminectomy was done at more than one level. In addition, posterior lumbar interbody fusion was performed in cases with degenerative listhesis. All procedures were performed by senior orthopaedic surgeon. According to this protocol, laminectomy with decompression was done in 2 cases, laminectomy and discectomy was done in 5 patients, laminectomy, discectomy with instrumented stabilization was done in 8 cases, and laminectomy, discectomy with posterior lumbar interbody fusion was performed in 3 patients.

Over all average length of follow up was 10.6 months (range 6 to 16 months). All patients after operation were examined for signs and symptoms.

RESULTS

The average age was 45.1 years (range 17-74 years). There were 45 males and 9 females. All the patients had symptoms for more than 3 months duration at presentation.

Preoperatively, 72% of patients presented with continuous severe low backache, 25% with occasional severe low backache, and 3% presented with occasional mild low backache. Three months postoperatively, 62.5% patients had no back pain and 37.5% had occasional mild low back pain. No patient had occasional severe or continuous severe low back pain. Intermittent claudication was present in 48% cases before operation which was reduced to only 8%. In 68% cases had sciatic pain before operation which was reduced to 4% after operation.

96.87% patients had no leg pain. All patients had preoperative claudication distance less than 100 m, but 93.75% patients had normal gait with walking distance more than 500 m and no claudication symptoms postoperatively. The most common level of involvement was L4-L5 (81.82% patients, followed by L5-S1 (54.55% patients. 54.55% patients showed involvement at more than one level. 93.74% patients had abnormal straight leg raising test [46.87% patients had straight leg raising positive below 30° and 46.87% patients had between 30° and 70°], but postoperatively all patients had normal straight leg raising test. Sensations were diminished in L 4 dermatome in 3 patients, L5 dermatome in 14 patients and S 1 dermatome in 8 patients. More than one dermatome was involved in 5 patients. Overall, 12 patients (62.5%) had shown sensory disturbance preoperatively, but postoperatively 17 of these 18 patients recovered normal sensory function. Motor weakness was present in 8 patients preoperatively, but postoperatively only 3 patients (18.75%) showed motor deficit.

At 3 month follow up, 18.75% patients showed excellent outcome, 62.50% showed good outcome, and 18.75% patients showed fair outcome. At 6 month follow up, 38.46% patients showed excellent outcome and 61.54% patients showed good outcome. At 1 year followup, 64.00% patients showed excellent outcome, 28% showed good outcome, and 8% showed fair outcome. No patient had poor outcome. Outcome of the patients improved as the time after surgery increased till 1 year and was sustained thereafter till the last

followup (only two patients showed decrease in their recovery rate which was due to prolapsed disc or canal stenosis at a different level).

The results of patients treated by conservative means and by epidural steroid did not give satisfactory results. Results of these three category was assessed by Oswestry disability index. According to this index best outcome was amongst surgical treatment. However treatment by all modalities showed improvement.

DISCUSSION

Purpose of this study was to evaluate the comparative efficacy of conservative, epidural steroids as well as surgical treatment. In the present study a total of 53 patients were evaluated 18 for surgical treatment, 25 for conservative treatment, and 10 for epidural steroids. The age of the patients were ranged from 25 years to 70 years with an average of 50 years. This shows that degenerative lumbar canal stenosis affects elderly population. This is in accordance with the study conducted by Hurry et al in which the mean age was 50 years in their series of 134 patients. Sandhu et al in 1976 reported 10 patients of lumbar canal stenosis in the age group of 36-63 years with an average of 50 years in series of 100 low back patients. In the present series sagittal diameter of canal gradually decreased from 17-21 (mean 19.2mm) mm at L1 to 10-16mm(13.4mm). In the present series, 62.7% patients presented with low backache and radicular symptoms and 23.8% with neurogenic claudication. Hardikar et al in 1988 in their series of lumbar canal stenosis patients reported symptoms in the following order of frequency low backache, radicular pain and neurogenic claudication. Johnson et al in 1993 reported a series of 32 patients of lumbar canal stenosis in which 24 patients had neurogenic claudication, 4 patients had radicular symptoms and all had low backache.

All cases in the present study had symptoms of classical neurogenic claudication. All patients presented with the history of localized backache as well as radicular. The history of localized backache ranged from 2 months to 30 months. Radicular backache ranged from 15 days to 90 days.

Initially all the patients were put on conservative treatment. Lumbar traction was given in patients with radicular symptoms. Few patients were treated by epidural steroids. Those patients who did not show clinical improvement were considered for decompression. All patients were also assessed by Oswestry disability score pre and post operatively. Radicular pain which was

initially present in 68% cases. After operation it was present in only 4% cases. Neurological claudication which was present in 48% cases before operation, it was present in 8% of the patients after operation.

The pain intensity of Oswestry index showed that preoperatively 37% of the cases had no relief with pain killers, 43% of the cases had very little relief and only 20% cases had moderate relief. Postoperatively after a year 29% did not need any pain killers, 34% had pain but could manage with out pain killers. In 14% cases pain killers gave moderate relief from pain and 23% cases got complete relief from pain after taking pain killers reflecting the vast improvement in the pain intensity of the patients. In the present study after one year of follow up pain persisted in 37%. This is comparable to the study by the Katz et al in which 31% continued to experience pain at 2 years of follow up.

CONCLUSION

We conclude from study although treatment by all modalities showed improvement. But in comparison to surgical treatment outcome of conservative and epidural steroid injection was not very satisfactory.

REFERENCES

1. Grob D, Humke T, Dvorak J. Degenerative lumbar spinalstenosis. *J Bone Joint Surg Am* 1995; 77:1036-1041.
2. Herno A, Airaksinen O, Saari T. The long-term prognosis after operation for lumbar spinal stenosis. *Scand J Rehabil Med* 1993; 25:167-171.
3. Atlas SJ, Keller RB, Robson D, et al. Surgical and nonsurgical management of lumbar spinal stenosis: four-year outcomes from the Maine Lumbar Spine Study. *Spine* 2000; 25:556-562.
4. Ganz JC. Lumbar spinal stenosis: postoperative results in terms of preoperative posture-related pain. *J Neurosurg* 1990; 72:71-74.
5. Raillardon L, Guigui P, Veil-picard A, Sluittel H, Deburge A. Long term results of surgical treatment of lumbar canal stenosis. *Rev Chir Orthop., Reparatrice Appar mot.* 2003, nov, 89(7), 621-3.
6. Amundson T, Weber H, Lilleus F. Lumbar spinal stenosis; clinical and radiologic features 1995; 20(10); 1178-1186
7. Airaksinen O, Herno A, Turnen V, Saari T, Suomlainen O. Surgical outcome of 438 patients treated surgically for lumbar spinal stenosis 1997; oct 1; 22(19); 2278-82.
8. Jonsson B, Annertz M, Sjoberg C, Stromqvist B. A prospective and consecutive study of surgically treated lumbar canal stenosis 1997; dec 15; 22(24); 2938-44.
9. Hurri H, Slatis P, Soini J, Tallroth K, Alaranta H, Laine T, Heliovaara M. Lumbar spinal stenosis; assessment of long term outcome 12 years after operative and conservative treatment. 1998; apr; 11(2); 110-5
10. Javid MJ, Hadar EJ. Long term follow up review of patients who underwent laminectomy for lumbar canal stenosis, a prospective study; 1998; july 89(1); 1-7
11. Cornefjord M, Byrod, Brisby H, Rydevik B. A long term (4-12 years) follow up study of surgical treatment of lumbar spinal stenosis 2000; dec 9(6); 563-70
12. Jolles BM, Porchet F, Theumann N. Surgical treatment of lumbar spinal stenosis; five year follow up *JBJS* 2001; sep; 83(7); 949-53
13. Hansraj KK, O'Leary PF, Cammisa FP Jr, Hall JC, Frasca CI, Cohen MS, Dorey FJ. Decompression, Fusion, and instrumentation surgery for complex lumbar spinal stenosis. 2001; mar; (384); 18-25
14. Jones, R.A.C. & Thomson, J.L.G. The narrow lumbar canal. A clinical and radiological review. *J. Bone & Joint Surg.* 1968; 50 B: p.no. 595-605
15. Inaoka M. and others: Radiographic analysis of lumbar spine for low back pain in the general population: *Archi. Of Orthop. and trauma surgery*; 2000; vol. 120; p. no. 380-5.

FEMORAL FRACTURES IN CHILDREN : EARLY FIXATION WITH ELASTIC NAIL

Garg I.K.*

Jain G.**

Singh A.**

Kumar L.*

ABSTRACT

In past there were different opinions and controversies about operative treatment of Paediatric femoral fractures. There has been a resurgence world wide for operative fixation and now with availability of elastic nail (titanium or steel), improvement in technique, availability of low cost of treatment shorter hospital stay, imaging and fewer complications, and better nursing care, early mobilization & early return to school, elastic nails is becoming choice of treatment in children of age group 5-14. A prospective study of

16 paediatric femur fractures was done which were treated with elastic nails (steel or titanium in age group of 5 -14 yrs and patients were evaluated according to Flynn criteria in which 15 cases showed good to excellent results.

INTRODUCTION

Femoral shaft fractures in children is a crippling injury, there are multiple methods of treatment in Age groups 5-14 years, as conservative methods i.e. traction, spica cast, traction followed by spica cast & operative methods i.e. external fixator, extra medullary fixation, with plates & screws, Intra medullary fixation with elastic nails. Treatment modalities may be influenced by age of the patient, level & pattern of fractures, to a great extent by availability of facilities and preference of surgeon. Generally out come tend to be good irrespective of modality of treatment used. A systemic review of literature provides little evidence to support one method of treatment over other. Over the past two decades the advantages of fixation and early mobilization has been increasingly recognised. Early discharge from the hospital & to reduce the treatment cost, better nursing care are the factor because of which newer technique are being popular. Elastic stable intramedullary Nailing (ESIN) is a load sharing internal splint that maintains the reduction and leads to Rapid Biological healing.

The present prospective study is aimed at the evaluations of intramedullary fixation with elastic nails in children with femoral shaft fractures fixation.

MATERIAL & METHODS

The study was conducted in Irwin hospital, Muzaffarnagar and Muzaffarnagar Medical College & Hospital, Begraipur muzaffarnagar from July 2013 to

August 2015. Total fifteen children (10 Boys 5 Girls) & 16 femoral shaft fracture in the Age group 5-14 years (Average Age 8-7) within 7 days of Injury (Average duration 3-7 days) were internally fixed with elastic nails. Fracture of right side was more common than left side (R -12, L - 4) three fracture were open thirteen were closed, Radiologically most common type was transverse type (8 cases) followed by oblique type (5 case) & comminuted type (03 cases). All cases were operated within seven days of injury. The surgery was performed in supine position on radiolucent table, under general or spinal anaesthesia. Two elastic nails of identical diameter were used, which according to Flynn et al formula. (Nail diameter = diameter of isthmus of medullary canal x 0.4mm).

Nails were inserted in retrograde manner one from medial side & one from lateral side Entry was made 2.5 cm proximal to physal line. The nails were pre bent so that apex of bowed nail rested to fracture level to ensure a good, equal recoil force. Nails were inserted proximally in divergent manner & within 2 cm of physal lines.

In post operative period patient were nourished in supine position with limb elevated. No external support was given in any case. Non weight bearing knee mobilization & quadriceps exercises were started within 1st week. Patients were allowed to change position and move in the bed as desired or according to need during daily living activities.

Patients were regularly followed up initially at a

* Asso. Prof.
** Asst. Prof.

Address for correspondence:
Dr. Irwin Kumar Garg
Associate Professor
Department of Orthopaedics
Muzaffarnagar Medical College
Begraipur, Dist. Muzaffarnagar (U.P.)

interval of 4 weeks for initial 3 months & than at a interval of 12 weeks till the completion of 1 year after operation or till the publication of this series which ever was earlier.

Partial weight bearing was started at 4-6 week & full weight bearing by 8-10 weeks depending on fracture geometry & callus formation eg. Bone healing.

Table 1
Showing type of fractures

S.No.	Type of fracture	No. of cases	Percentage
1	Transverse	9	56.25
2	Oblique	4	25
3	Comminuted	3	18.75

Table 2
Showing level of fractures

S.No.	Level of fracture	No. of cases	Percentage
1	Upper third	5	31.25
2	Middle third	8	50
3	Distal third	3	18.75

Table 3
Showing closed or open fractures

S.No.	Closed/open fracture	No. of cases	Percentage
1	Closed	14	87.5
2	Open fracture	2	12.5

RESULTS

All 15 patient were available for evaluation after a mean of 12 month of union or till union. The union was achieved in all cases in a mean time 7-8 weeks. (5-10 weeks), the results were excellent in 13 cases (81.25%) good in 2 cases (12.5%) and poor in 1 case (6.25%) varus angulation of $<10^\circ$ Full weight bearing was started at 8-12 weeks with an meantime of 8.5 weeks was present in 2 patients, $> 10^\circ$ in 1 patient. No limb length discrepancy or of < 1 cm was present in 13 cases, of < 2 cm varus was present in 3 cases & of > 2 cm was present in 1 case. One case had minor soft tissue infection at entry site, & pain due to irritation by nail. The mean hospital stay was 7 days (4-12 days). Nails were removed after union earliest after 6 month of Surgery but routinely after 8-9 months. No complications were associated with the nail removal procedure and no refractures were observed

DISCUSSION

Conservative treatment is the accepted standard as for young children but complications such as malunion, joint stiffness & delay in functional recovery are common in older children if managed in this manner and also conservative treatment results in longer hospital stay, more burden of financial losses to family and hospital.

Elastic nailing has been advocated but controversy regarding Ideal implant to treat paediatric femoral fractures still exists.

In the Present series Elastic nail was used as a mode of fixation in different type of femoral fracture in children between ages 5-14yrs. sixteen were operated and evaluated Radiologically. Clinically & functionally for the efficacy of Elastic nails. Several studies have shown good healing rates with lesser complications. Oh et al 14 observed that all 31 fractures in his series healed with in 12 weeks (mean 10.5 weeks) without delayed union. Bruechsen chuers et al reported that in 42 patients treated with ESIN fractures healed at a mean of 88 days from Injury Houshian et reported median union time of 7(5-9) weeks. In our series also mean union time was 7.8 weeks (5-10 weeks)

Flynn et al and mazacla et al observed walking without support at an average of 8.5 weeks and 9.5 weeks respectively. In our series also mean full weight bearing averaged 8.10 weeks (8-14 weeks). Early mobilization have benefits like less hospital stay, less school days loss, less joint stiffness & muscle atrophy, Psychological & economical Advantage.

Harden et al showed that the hospital stay in non Surgical group averaged 28 days and in Surgical group averaged 12 days and surgical group averaged 12 days which was significant in present series average hospital stay was of 12 days less hospitalization time has resulted in the increase in hospital bed occupancy and early return of patients to their home environment, earlier return of parents to their work.

No cases infection was seen in result series. This procedure require a small incision & less operative time that's why infections is not problem with this procedure, Herdon et al showed the similar results regarding Infection. The results of presen series are comparable to those of other series. It has definite advantages over other like early union early mobilization early weight bearing, high patients satisfaction rate scar acceptance. Easy implant removal. Elastic nails do not endanger either epiphyses or blood supply of femoral head.

FEMORAL FRACTURES IN CHILDREN EARLY FIXATION WITH ELASTIC NAIL

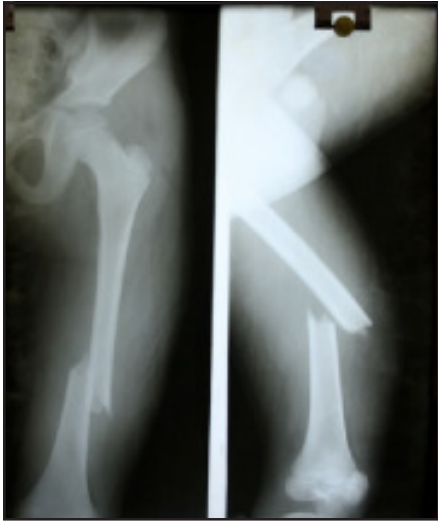

Fig. 1 : Pre operative X-Ray

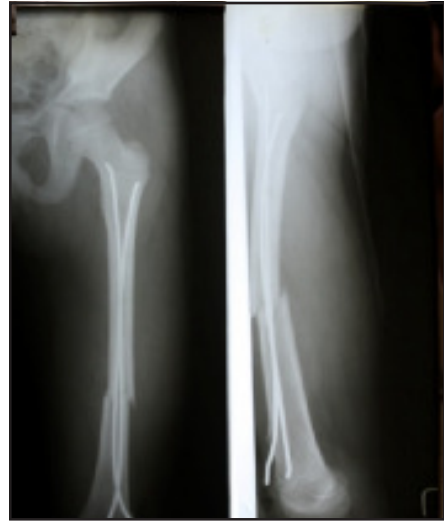

Fig. 2 : Post Operative X-Ray

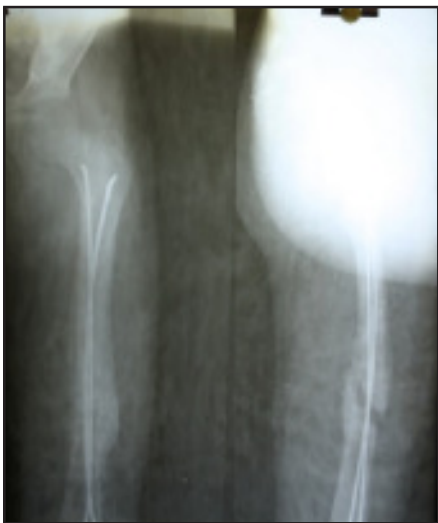

Fig. 3 : Post Operative X-Ray at 5 Weeks

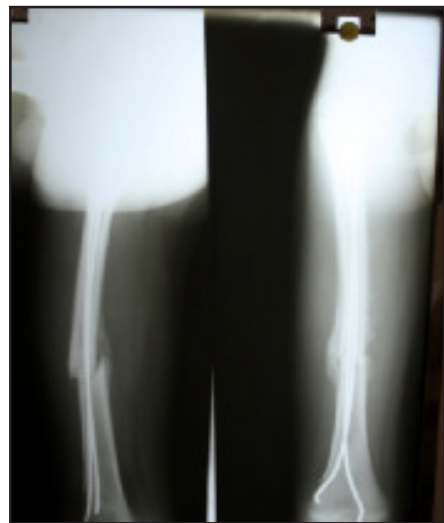

Fig. 4 : Post Operative X-Ray at 9 Weeks



Fig. 5 : Patient Standing Unaided At 9 weeks



Fig. 6 : Patient Standing on Fractured Limb Unaided at 9 Weeks



Fig. 7 : Patient Squatting at 9 Weeks

Table 4
Showing out come as per Flynn et al criteria

S. No.	Criteria	No. of cases	Results
1	Limb Length Discrepancy	Less than < 1 cm	13
		Less than < 2 cm	03
		More than > 2 cm	01
2	Angular Deformity	Less than < 5°	13
		Less than < 10°	02
		More than > 10°	01
3	Pain	Absent	15
		Present	01
4	Complications	Absent	15
		Present	01
		(Minor soft tissue infection)	

CONCLUSION

In paediatric femoral fracture requiring operative stabilization, closed intra medullary nailing with elastic nail is a excellent method. Though present data does not shows that superior to other methods, yet this method has an advantage of providing better rehabilitation with biological healing of fracture, considerably reduced hospital stay resulting in early return of the patients to their home environment, low cost of treatment & psychosocial advantages, because of rapid fracture healing, early weight bearing, minimal disturbance of growth, early return to home environment, psychosocial & economic advantages intramedullary nailing with elastic nails may be considered to be a method of treatment for fracture shaft of femur in children of 5-14 yrs of age.

REFERENCES

- Acta Orthop Traumatol Turc. 2002;36(3): 220-7. Intramedullary stabilization of pediatric diaphyseal femur fractures with elastic Ender nails Ozturkmen Y, Dorgrul MB, Karli M.
- Flynn JM, Hresko T, Reynolds RA, et al. Titanium elastic nails for Pediatric femur fractures: A multicenter study of early results with analysis of complications. J Pediatr Orthop. 338: 60-73.
- Galpin RD, Willis RB, Sabano N. Intramedullary nailing of pediatric femoral fractures. Jpediatr Orthop. 1994; 14(2): 184-9.
- Houshian S, Gothgen CB, Padersen NW, et al. femoral shaft fractures in children. Elastic stable intramedullary nailing in 31 cases. Acta Orthop Scand. 2004; 75(3): 249-51.
- Herndon WA, Mahnken RF, Yngve DA, et al. Management of femoral shaft fractures in the adolescent. J Pediatr Orthop. 1989; 9: 29-32.
- J Am Acad Orthop Surg. 2004 Sep-Oct;23(5):347-5. Management of pediatric femoral shaft fractures. Flynn JM, Schwend RM.
- J Pediatr Orthop. 2002 Jul-Aug;22(4):247-7. Mechanical properties of different combinations of flexible nails in a model of a pediatric femoral fracture. Kiely N. 9a-Injury. 2000 Dec;31(10):769-71. Operative treatment of femoral shaft fractures in children: a nine-year experience in a Saudi Arabian population. Mirdad T.
- J.M. Flynn, D Skaggs, P. D. Sponseller, T. J. Gonley, R. M. Kay and K. K. Leitch, "The Operative Management of Pediatric Fractures of the Lower Extremity," The Journal of Bone and Joint Surgery, Vol. 84, No. 12, 2002, pp. 2288- 2300.
- J.M. Flynn, L. Luedtke, T. J. Ganley and S. G. Pill, Titanium Elastic Nails for Pediatric Femur Fractures Lesons from the Learning Curve," The American Journal of Orthopaedics, Vol. 31, No. 2, 2002. 71-74.
- J.N. Ligier, J. O. Metaizeau, J. Prevot and P. Lascombes "Elastic Stable Intramedullary Nailing of Femoral Shaft Fractures in Children/ The Journal of Bone and Joint Surgery, Vol. 70, No. 1,1988, pp. 74-77.
- Kasser JR, Beaty Jh. Femoral shaft fractures. In: Rockwood and Wilkins Fractures in Children. 5th ed. New York: Lippincott Williams and Wilkins; 2001. 941-80.
- K.E. Buechsenschuetz, C.T. Mehlman, K. J. Shaw, A. H. Crawford and F. B. Immerman, : Femoral Shaft Fractures In Children: Traction and Casting Versus Casting Versus Elastic Stable Intramedullary Nailing," The Journal of Trauma, Vol. 53, No. 5, 2002, pp. 914-921.
- Kiely,Nigel.Mechanical properties of different combinations of flexible nails in a model of a paediatric femoral fracture. J Paed Orthop. 2002;22:769-771.doi:10.1017/00004694-200207000-00002.
- Oh CW, Park BC, Kim PT, et al. Retrograde flexible intramedullary nailing in children's femoral fractures. Int Orthop (Sicot). 2002; 26(1): 52-5.
- Pradeep, Kumar. Indian Journal of Orthopaedics. 2001.pp.242-244.
- Rev Chir Orthop Reparatrice Appar Mot. 2003 Nav; 98 (70):599-604. Femoral shaft fracture in children: treatment with early spica cast Beme D, Mary O, Damsin JP, Fillipe G.
- Unfallchirurg.2004 Sep;107(9):744-9. Pitfalls and complications of elastic intramedullary nailing (ESIN) of femoral fractures infancy Jubel A, Andermahr J, Prokop A, Bergmann H, IsenbergJ, Rehm KE.
- Wright JG. The treatment of femoral shaft fractures in children: a systemic overview and critical appraisal of the literature. Can J Surg. 2000; 43(3): 180-9.

A RARE PRESENTATION OF GIANT CELL TUMOR INVOLVING THE PROXIMAL PHALANX OF GREAT TOE - A CASE REPORT

Pradhan C.S.*

Mohapatra N.C.**

Rana R.***

Das B.****

ABSTRACT

Giant cell tumor (GCT) involving the phalanges of foot is very rare and only few cases have been reported in the literature¹. This case is about a 18 year old male presenting with pain swelling of the right great toe and core needle biopsy revealing the diagnosis of giant cell tumor involving the proximal phalanx of great toe. Patient was treated by curettage & iliac crest bone grafting⁵. Early diagnosis and curettage & bone grafting offers good chances of cure in GCT presenting unusual sites such as the phalanges of foot.

INTRODUCTION

Giant cell tumor (GCT) is a benign aggressive tumour of bone with features of local recurrences, potential for metastasis and malignant transformation. It consists of spindle shaped and ovoid cells uniformly interspersed with multinucleated giant cells. Giant cell tumour accounts for approximately 6% of all bone tumours and constitutes 20% of benign bone tumors. Phalanges of foot are a rare site of occurrence. We report a case of GCT of proximal phalanx of right great toe diagnosed in a 18-year-old man.

CASE SUMMARY

A 18-years- old man presented with history of swelling of right great toe for 4 months and pain at the same site for 3 months. Swelling was insidious in onset and has progressively increased in size. Pain was mild to moderate in intensity, dull aching, continuous relieved by taking non-steroidal analgesics and rest.

There was a diffuse swelling over the base and proximal part of left great toe. The overlying skin was stretched. Extent of the swelling was from distal one third of 1st metatarsal to interphalangeal joint of toe. Swelling was hard in consistency and overlying skin was free. There was painful restriction in range of movements of left great toe and distal neurovascular bundle was intact. Dorsal and lateral view of left foot showing swelling. The differential diagnosis was GCT, aneurysmal bone cyst and simple bone cyst. The serum biochemistry and chest X ray were normal. Plain radiographs of the right foot

revealed an Expansile Osteolytic lesion of the proximal phalanx of right great toe with intact cortex.

Core needle biopsy showed giant cell tumor without features of malignancy. The tumor was approached by anteromedial approach. Large window was made in bone and tumor materials were curetted out. It was washed with copious amount of saline then high speed burr was used to complete the curettage. Cancellous bone graft was taken from right iliac crest⁵ and was used to fill the cavity. There was no evidence of malignancy or breach in cortex margins was negative for the tumor. Follow up of 5 months has not revealed any sign of recurrence of the tumor.

DISCUSSION

The majorities of giant cell tumors is solitary and occur at the epiphysio-metaphyseal region of long bones. Approximately 50%-70% of giant cell tumors occur near the knee with distal femur and proximal^{1,2} tibia being the most commonly involved sites. The other common sites are radius, sacrum and the proximal humerus. Foot is a rare site for GCT, accounting for about 1% of giant cell tumors.³ Majority of GCT of foot occur in either calcaneus or talus; the occurrence in phalanges is very rare. Literature search yields only five reported cases of 4-8 giant cell tumor involving phalangeal bone of foot. Literature review on case reports of GCT involving phalanges of the foot are characterized by higher incidence of multicentricity, younger age at 9 presentation and shows more aggressive behaviour.⁸

* Asst. Prof.
** Asso. Prof.
*** Resident

Address for correspondence:
Dr. N.C. Mohapatra
Asso. Prof.
Dept. of Orthopaedics
SCB Medical College, Cuttack
Orissa

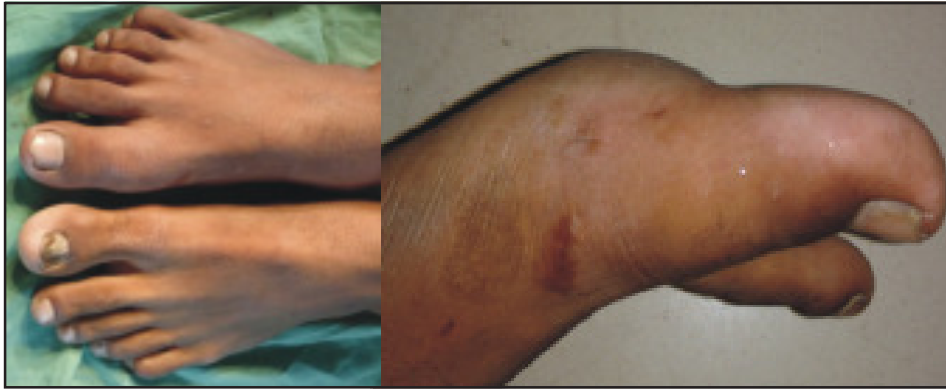

Fig. 1 : Preoperative Clinical Photo

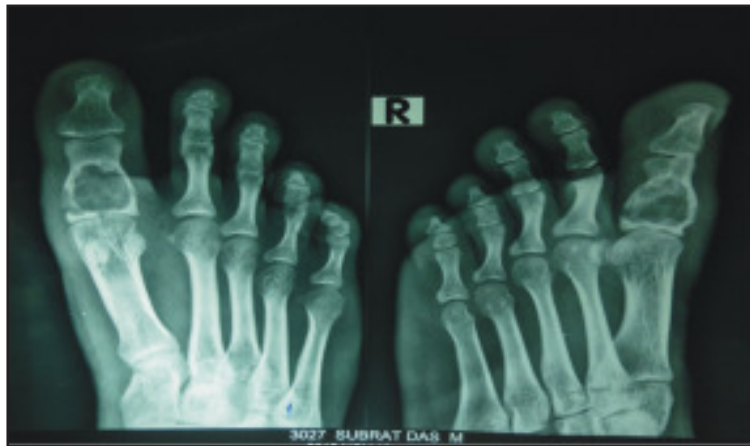


Fig. 2 : Preoperative X Ray, AP & Lateral

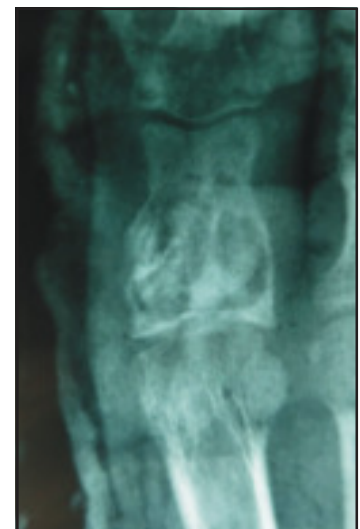
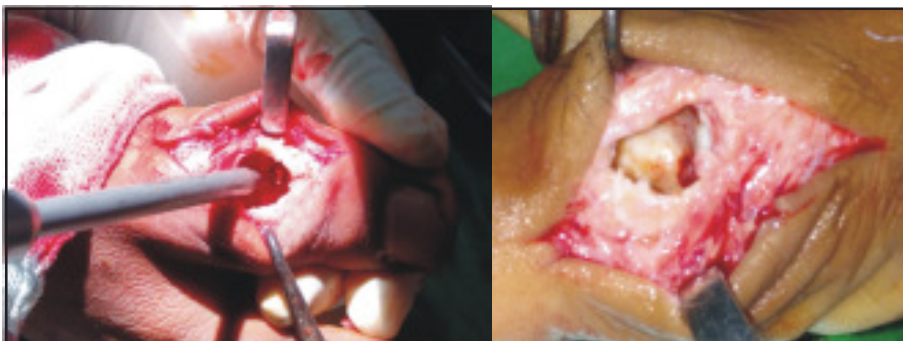
Fig. 3 : Post-Operative Radiograph

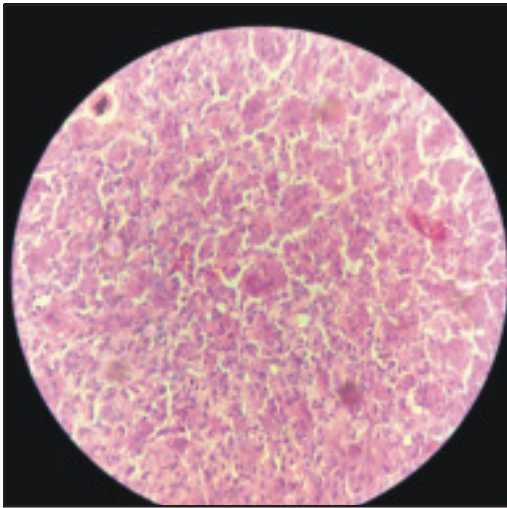


Fig. 4 : Histopathology

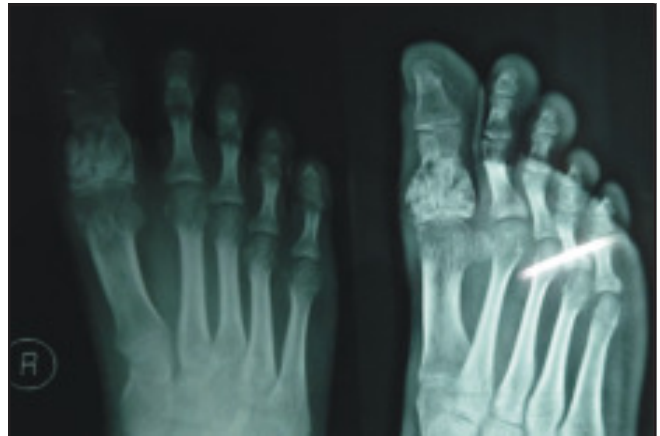

Fig. 5 : Three Month follow up

It usually present with pain and swelling and diagnosis is frequently delayed as symptoms may initially be attributed to non-specific foot pathology. Radiologic features of GCT at unusual location are non specific.

The standard treatment options for GCT are curettage, extended curettage or enbloc resection. Cryosurgery and radiotherapy have also been used as treatment modalities.

Phalangeal bones of the foot are very rare location of giant cell tumors. It is very important to choice of treatment depends on the aggressiveness of tumor, site and patient characteristics.⁷ Curettage is also a good option when tumor is well encapsulated and there is no breach in cortex. Cryosurgery has been used as a physical adjunct to curettage in treatment of GCT. The role of radiotherapy is limited in GCT due to high propensity for malignant transformation. Its use is reserved for specific lesions of spine with cord compression and lesion which are un-resectable. Due to chance of recurrence, active surveillance of patient is recommended.³

CONCLUSION

Phalangeal bones of foot are very rare location of giant cell tumors. These are aggressive⁷ and sometimes multicentric. When there is no malignant transformation

or breach in cortex curettage and bone grafting is a good option of treatment.

REFERENCES

1. Unni K, Inwards CY. Dahlin's bone tumors: general aspects and data on 10,165 cases. 6th ed. Philadelphia, PA: Lippincott Williams &Wilkins; 2010.
2. Turcotte RE. Giant cell tumor of bone. *OrthopClin North Am.* 2006 Jan;37(1):35-51. 1 IJRRMS VOL-3 No.3 JULY - SEP 2013 ||||
3. Biscaglia R, Bacchini P, Bertoni F. Giant cell tumor of the bones of the hand and foot. *Cancer.* 2000 May 1;88(9):2022-32.
4. Misra US, Dhaon BK, Gupta SC, Dwivedi SC. Giant cell tumour of proximal phalanx of great toe. *J Indian Med Assoc.* 1977 Nov 1;69(9):204-5.
5. Alvarez Ramos A, ValverdeGarcía JA, García Alonso MG. Giant cell tumor of the foot phalanges in children: a case report. *J PediatrOrthop B.* 1999 Apr;8(2):132-5.
6. Fujisawa Y, Takahashi T, Kawachi Y, Otsuka F. Giant cell tumor of the distal phalanx of the foot. *Eur J Dermatol.* 2006 MarApr;16(2):204-5.
7. Dridi M, Annabi H, Ben Ghazlen R, Abdelkefi M, Trabelsi M. Giant cell tumour of a phalanx in the foot: a case report. *ActaOrthop Belg.* 2008 Apr;74(2):273-5.
8. Bachhal V, Rangdal S, Saini U, Sament R. Giant cell tumor of distal phalanx of great toe. A case report. *Foot (Edinb).* 2011 Dec

EVALUATION OF OUTCOME OF INTERTROCHANTRIC FEMORAL FRACTURES TREATED WITH PROXIMAL FEMORAL NAIL IN 200 PATIENTS

Sharma N.*
Singh S.P.*

Agrawal A.*
Singh V.*

Bhargava R.**
Krishna V.*

ABSTRACT

Background: Intertrochanteric femoral fracture is a common problem in elderly. These fractures are difficult to treat because of associated osteoporosis and frequent posteromedial comminution. There is an ongoing debate regarding the ideal implant to fix these types of fractures in our part of the world, some surgeons prefer dynamic hip screws while others prefer proximal femoral nail.

Materials and Methods: A total of 200 Intertrochanteric femoral fracture patients with an average age of 66 years were operated upon between 2006 to 2010. We were able to treat 176 patients by closed reduction whereas 24 patients required minimal exposure open reduction. Patients were evaluated on the basis of functional and radiological assessment at regular follow ups. The mean follow up was 24 months.

Results: Anatomical reduction was achieved in 186 cases. Union was achieved in 190 patients in 4.5 months whereas 10 patients had delayed union. Assessment of hip function by Harris hip score showed that at 1 year follow up 94% of the patients had excellent to good score which increased to 100% at 2 years.

Conclusion: Proximal femoral nailing is better method for fixing Intertrochanteric fractures regardless of the fracture pattern. This method of fixation provides early mobilization with minimal complications. We recommend proximal femoral nail for all Intertrochanteric fractures especially with posteromedial comminution.

Keywords: Posteromedial comminution, Proximal femoral fracture, Proximal femoral nail

INTRODUCTION

Fractures of the proximal femur and hip are relatively common injuries in elderly. These fractures are associated with substantial morbidity and mortality. 30% of elderly patients die within 1 year of fracture. The total number of hip fractures in men and women in 1990 was estimated to be 338,000 and 917,000 respectively, a total of 1.26 million.¹ Assuming no change in the age and sex specific incidence, the number of hip fractures is estimated to approximately double to 2.6 million by the year 2025 and 4.5 million by the year 2050.² The biomechanical advantages of intramedullary (IM) implants make Gamma nail (GN) and proximal femur nail (PFN) an attractive option especially in unstable fractures.³ Initial reports have suggested that intramedullary nails may have an advantage over side plate devices in unstable fractures but have not demonstrated a clear superiority and have a reported complication rate of around 20%.⁴⁻⁶ The incidence of neck screw cutout has reduced considerably with

improvements in the surgical technique but still remains the most common mode of fixation failure with IM implants.^{7,8} We are presenting a prospective study of two hundred Intertrochanteric fractures operated using proximal femoral nail. The clinical result in terms of fracture union, early joint movements, early weight bearing and rapid discharge from hospital have been excellent.

MATERIAL AND METHODS

Between 2006 and 2010, 200 Intertrochanteric fractures were operated upon by proximal femoral nailing. There were 72 males and 128 females (Chart 1). The mean age was 66 years (50 to 99 years). As recommended by the AO/ASIF, the fractures were classified on the basis of the preoperative radiographs as 31-A1 (stable pertrochanteric), 31-A2 (unstable pertrochanteric), 31-A3 (unstable intertrochanteric). 50 patients (25%) had type A1 fracture, 98 patients (49%) had type A2 fracture and 52 patients (26%) had type A3

* Consultant
** Professor & Head

Address for correspondence:
Dr. Ashish Agrawal (D.Ortho, D.N.B. Ortho)
60, Mahashweta Nagar,
Near ISKCON Temple, Ujjain, (M.P.)
Email: drfriendlyashish@gmail.com
Mobile: 9755607606

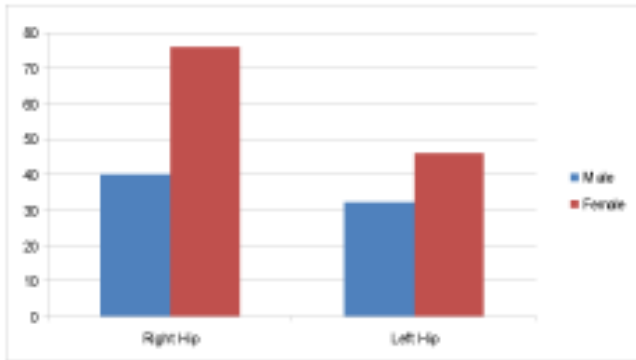


Chart 1 : Side and Sex Distribution of the patients

fracture (Chart 2). All patients were operated upon after complete pre-anaesthetic work up. 90% of the patients were operated within 2 days of admission, 8 % were operated within 2 to 5 days while remaining 2% were operated within 5 to 7 days of admission (Chart 3). 176 patients were operated by close reduction while 24 patients required open reduction by minimal exposure technique. Reduction criteria for the fracture was according to Baumgaertner's criteria.⁹

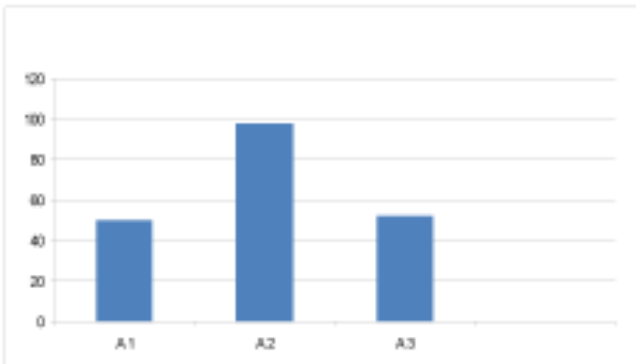


Chart 2 : Distribution of patients according to the AO classification

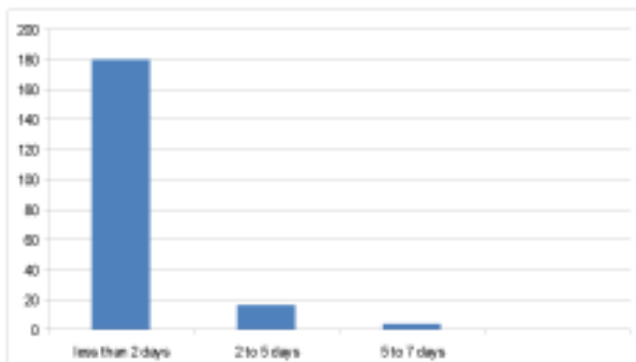


Chart 3 : Time from admission to surgery

25 patients had associated injuries like distal end radius fracture and clavicle fracture. All the patients were operated in a supine position on the fracture table. Opposite limb was kept in abduction so that it should not come in the way of image intensifier intraoperatively. Limb to be operated was kept in 20 to 30 degree of adduction and 5 to 10 degree of internal rotation. This position helped in reaming and nail placement. Reduction was checked under image intensifier before painting and draping. Longitudinal incision of about 4 cm was given above the greater trochanter in line with the shaft of the femur. Entry point was taken just medial to the tip of greater trochanter. Guide wire was placed and sequential reaming was done. Proximal reaming was done up to 13 mm. PFN of 24 cm length was used in all cases. After nail insertion proximal locking was done first taking care of version and reduction. Size of the hip pin used varied from 80 to 105 mm while size of the hip pin used varied from 65 to 90 mm. In the neck hip screw was kept in inferior position in anteroposterior view and central in lateral view. In the head, the position of the hip screw was either central or inferior.

At times, when there was posterior sag of distal fragment not correctable by closed means, open reduction by minimal exposure was done using a blunt spike or bone hook to correct the sag and reduction was maintained during proximal locking. Depending on the fracture configuration single or double distal locking was done using the distal locking zig attachment of the nail. Only dynamic locking was done for stable fracture patterns while static plus dynamic distal locking were done for unstable fracture patterns.

Patients were nursed with limb elevation to reduce post operative swelling and pain. Patients were allowed knee and hip mobilization on the second day of operation and were allowed toe touch weight bearing walking from third post operative day. Patients were gradually encouraged to increase the weight bearing as per the pain and comfort. Patients were allowed to walk full weight bearing as soon as they were comfortable doing it, usually at around 3 months postoperatively. Post operatively patients were followed at 2 weeks, 6 weeks, 3 months, 4.5 months, 6 months and 1 year, 2 years and 3 years after surgery for evaluation. At follow-ups patients were followed radiographically till the time union was seen. Harris hip score was used for the functional assessment of the patients. The mean follow up period was 24 months. Only patients with a minimum follow up period of 12 months were included in the study.

RESULTS

Average hospital stay for the patients was 10 days.

Average blood loss during the surgery was 200 ml. Average surgical time was 52 minutes. We were able to get near anatomical reduction in 186 cases. Suture removal was done at around 2 weeks. Consolidation time for the fracture was around 4.5 months in 190 patients (95%) (Chart 4). At 6 month follow up, majority of the patients were pain free, minimal limp was seen in 52 patients (26%), which may be due to damage to abductor mechanism during surgery or due to slight shortening of the affected limb. 85% of the patients were community ambulators, with or without support, indicating the effectiveness of PFN in dealing with these fractures. Pain and Limp disappeared at 1 year follow up in all patients.

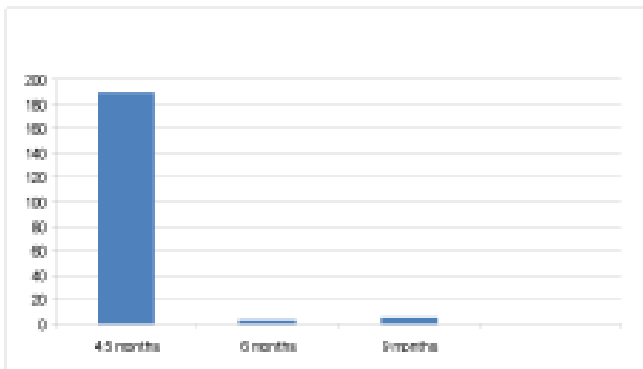


Chart 4 : Union time in months

Evaluation by the Harris hip score showed that 88% of the patients had excellent to good score at 6 month follow up (120 excellent and 48 good), at 1 year follow up 94% of the patients had excellent to good score (158 excellent and 30 good). 166 patients were available for follow up at 2 years, all of them showed excellent to good score (152 excellent and 14 good). (Chart 5)

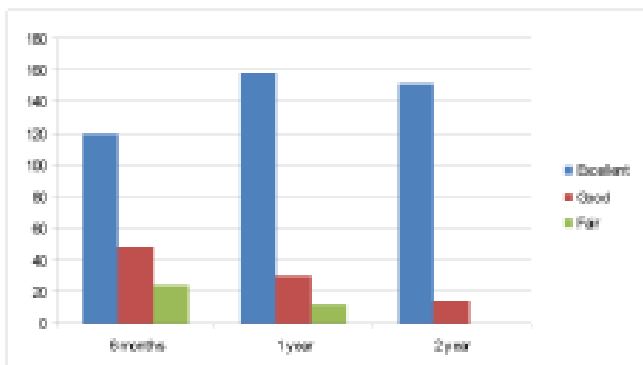


Chart 5 : Harris Hip Score at 6 months, 1 year and 2 year post-operatively

There was no case of implant breakage, screw cut out from femoral head and neck, loss of fracture reduction or femoral shaft fracture in our study. The overall reoperation rate of 4% was comparable with the reported rate of 1.2 -10%.^{10,11}

COMPLICATIONS

Out of 200 patients, 18 had complications (9%). There were 10 delayed union (5%) in our study all being unstable fractures. 4 out of 10 delayed union cases were infected. All infections were treated with 6 weeks of antibiotics which were given according to culture and sensitivity report and of them, only 1 case required open debridement due to persistent discharge and deep infection. All 4 infected cases eventually showed healing of fracture (average time 6 months). Remaining 6 non infected delayed union patients required revision surgery in the form of secondary bone grafting, which was done at 3 months. All these 6 patients showed union, 6 months after the bone grafting.

6 (3%) patients had Z deformity in which hip pin moved medially and hip screw moved laterally (Figure 1). 2 (1%) cases had reverse Z deformity in which hip pin moved laterally and hip screw moved medially (Figure 2). These patients were treated with screw removal once union was seen on X rays. Also, these patients were kept non weight bearing till the time radiological union was achieved.

DISCUSSION

There is ongoing debate about ideal implant needed for Intertrochanteric fractures in our part of the world. Associated old age of the patients and the varying comminution pattern of the fracture adds to the dilemma. Use of proximal femoral nail in the management of such fractures is increasing. A intramedullary device inserted by means of a minimally invasive procedure is better in elderly patients.¹² Biomechanically intramedullary nails are stronger than extramedullary devices. Closed reduction of the fracture preserves the fracture hematoma, an essential element in the consolidation process.

P.F.N. allows the surgeon to minimize soft tissue dissection thereby reducing surgical trauma, blood loss, chances of infection and wound complications.

As the mobilization of the patient is faster and earlier with the use of P.F.N., secondary complications related to prolonged bed rest and hospital stay are avoided. This is of great importance in the elderly patients due to both medical and social reasons.

Because of the large distal diameter, gamma nail

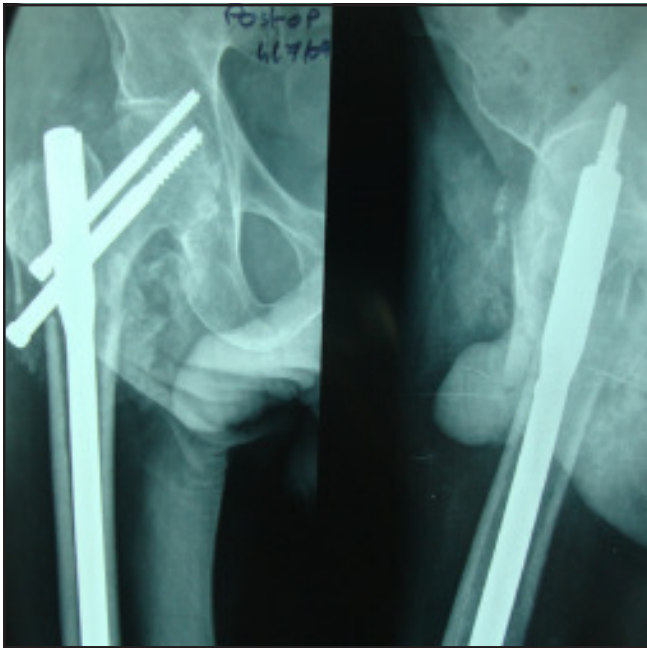


Fig. 1 : 'Z' effect

was having high incidence of femoral shaft fracture at the nail tip which is not the case in PFN.¹³ In an experimental study, Götze compared the load ability of osteosynthesis of unstable per- and subtrochanteric fractures and found that the PFN could bear the highest loads of all devices.¹⁴

We would like to share a tip at this juncture related to the common intraoperative difficulty encountered with PFN. In many cases distraction was evident at the fracture site because of the entry point placed directly in the region of fracture site. This occurs due to intact cortex on the medial side of the entry point which generally remains unreamed. This is not a common complication with Gamma nail.¹⁵ To take care of this issue we recommend breaking of this unreamed cortex medial to the nail with the help of a curette or a rongeur, before proceeding to the reaming of femoral canal.

Another tip that we would like to share is to prevent the Nail and the Proximal fragment from going into varus, we used to temporarily hold the proximal fragment with the help of Steinmann pin placed perpendicular to the outer cortex without obstructing the passage of the guide wire and the nail subsequently. This helped in achieving anatomical reduction of the fracture and also correct placement of the nail.

This allowed good reduction of the fracture along with good compression at fracture site. There are some common complications associated with PFN. There are

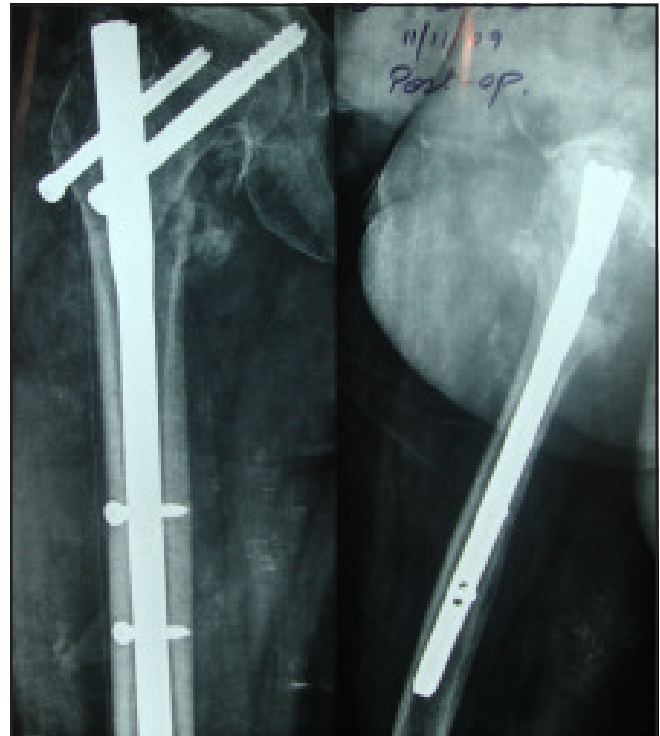

Fig. 2 : Reverse 'Z' effect

chances of Z effect if hip pin is longer than lag screws with medial migration of hip pin and lateral migration of lag screw. At times, this may require removal of the screw. In literature incidence of Z effect is 2 to 7%.¹⁶⁻¹⁷ In our study the incidence of Z effect was 3%. We used hip pin 15 mm smaller than lag screw to prevent the Z effect. There were 2 (1%) cases with reverse z effect deformity in which hip pin moved laterally and hip screw moved medially, occurring mainly due to poor purchase of the hip pin in the bone or when size of the hip pins used was too small.

We recommend use of PFN for all Intertrochanteric femoral fractures irrespective of the fracture pattern. In cases where there is posterior and medial comminution, DHS leads to uncontrolled collapse¹⁸ whereas PFN in such cases provide medial buttress and prevent excessive medialisation.¹⁹⁻²⁰

CONCLUSION

Proximal femoral nailing is a minimal invasive procedure best suited for the management of Intertrochanteric femur fractures in the elderly. Biomechanically it is a stronger construct. It provides early mobilization thereby preventing secondary complications like pulmonary infections, venous

thrombosis, pressure sores, and generalized physical deterioration. Proximal femoral nailing is especially useful in comminuted proximal femoral fractures. We recommend proximal femoral nail for all intertrochanteric fractures regardless of the fracture pattern.

REFERENCES

1. RY Hinton and GS Smith. The association of age, race, and sex with the location of proximal femoral fractures in the elderly. *J. Bone Joint Surgery Am.*, Jun 1994; 76: 924 - 950.
2. Bullberg B, Johnell O, Kanis JA. World-wide projections for hip fracture. *J. Osteoporosis Int.* 1997; 7(5):407-413.
3. Anglen JO, Weinstein JN. American Board of Orthopaedic Surgery Research Committee. Nail or plate fixation of intertrochanteric hip fractures: Changing pattern of practice. A review of the American Board of Orthopaedic Surgery database. *J Bone Joint Surg . Am.* 2008; 90:700-7. [PubMed: 18381305].
4. Sadowski C, Lübbecke A, Saudan M, Riand N, Stern R, Hoffmeyer P. Treatment of reverse oblique and transverse intertrochanteric fractures with use of an intramedullary nail or a 95 degrees screw-plate: A prospective, randomized study. *J Bone Joint Surg Am.* 2002; 84-A:372-81. [PubMed: 11886906]
5. Saudan M, Lübbecke A, Sadowski C, Riand N, Stern R, Hoffmeyer P. Pertrochanteric fractures: Is there an advantage to an intramedullary nail?: A randomized, prospective study of 206 patients comparing the dynamic hip screw and proximal femoral nail. *J Orthop. Trauma.* 2002; 16:386-93. [PubMed: 12142826].
6. Werner-Tutschku W, Lajtai G, Schmiedhuber G, Lang T, Pirkel C, Orthner E. Intra- and perioperative complications in the stabilization of per- and subtrochanteric femoral fractures by means of PFN. *Unfallchirurg.* 2002; 105:881-5. [PubMed: 12376894].
7. Barton TM, Gleeson R, Topliss C, Greenwood R, Harries WJ, Chesser TJ. A comparison of the long gamma nail with the sliding hip screw for the treatment of AO/OTA 31-A2 fractures of the proximal part of the femur: A prospective randomized trial. *J Bone Joint Surg Am.* 2010; 92:792-8. [PubMed: 20360500].
8. Pervez H, Parker MJ, Vowler S. Prediction of fixation failure after sliding hip screw fixation. *Injury.* 2004; 35:994-8. [PubMed: 15351665].
9. Baumgaertner MR, Curtin SL, Lindskog DM. Intramedullary versus extramedullary fixation for the treatment of intertrochanteric hip fractures. *Clin Orthop Relat Res.* 1998; 348:87-94. [PubMed: 9553538].
10. Harrington P, Nihal A, Singhania AK, Howell FR. Intramedullary hip screws versus sliding hip screw for unstable proximal femoral fractures in the elderly. *Injury.* 2002;33:23-8. [PubMed: 11879828].
11. Adams CI, Robinson CM, Court-Brown CM, McQueen MM. Prospective randomized controlled trial of an intramedullary nail versus dynamic screw and plate for trochanteric fractures of the femur. *J Orthop Trauma.* 2001;15:394-400. [PubMed: 11514765].
12. Rosenblum SF, Zuckerman JD, Kummer FJ, et al. A biomechanical evaluation of the Gamma nail[J]. *J Bone Joint Surg(Br)*, 1992,74(3):352-357.
13. Albareda J, Laderiga A, Palanca D et al. Complications and technical problems with the gamma nail. *Int Orthop*, 1996 ; 20 : 47-50.
14. Gotze B, Bonnaire F, Weise K and Friedl HP. Belastbarkeit von Osteosynthesen bei instabilen per- und subtrochanteren Femurfrakturen: experimentelle Untersuchungen mit PFN, Gamma-Nagel, DHS Trochanter stabilisierungs plate 95°-Kondylenplatte und UFN Spiralklinge. *Aktuelle Traumatologie* 1998;2(8):197-204.
15. Christian Boldin, Franz J Seibert, Florian Fankhauser, Gerolf Peicha Wolfgang Grechenig and Rudolf Szyszkowitz . The proximal femoral nail (PFN)-a minimal invasive treatment of unstable proximal femoral fractures A prospective study of 55 patients with a follow-up of 15 months. *Acta Orthop Scand* 2003; 74 (1): 53-58 .
16. T Morihara Y Arai, S Tokugawa, S Fujita, K Chatani, T Kubo . Proximal femoral nail for treatment of trochanteric femoral fractures . *Journal of Orthopaedic Surgery* 2007;15(3):273-7.
17. Utrilla AL, Reig JS, Muñoz FM, Tufanisco CB. Trochanteric gamma nail and compression hip for trochanteric fractures: A randomized, prospective, comparative study in 210 elderly patients with a new design of the gamma nail. *J Orthop Trauma.* 2005;19:229-33. [PubMed: 15795570].
18. F Seinsheimer . Subtrochanteric fractures of the femur *J Bone Joint Surg Am* 1978; 60:300-306.
19. Kakkar R, Kumar S, Singh AK. Cephalomedullary nailing for proximal femoral fractures. *Int Orthop.* 2005;29:21-4. [PMCID: PMC3456955][PubMed: 15647914]
20. Schipper IB, Steyerberg EW, Castelein RM, van der Heijden FH, den Hoed PT, Kerver AJ, et al. Treatment of unstable trochanteric fractures. Randomised comparison of the gamma nail and the proximal femoral nail. *J Bone Joint Surg Br.* 2004;86:86-94. [PubMed: 14765872]



TM

**INDEX
COPERNICUS
INTERNATIONAL
2009**

JOURNAL MASTER LIST

ISI Patent Pending

1566 IND **Journal of Orthopaedics, The**

pISSN: 0975-7333

ICV: 2.79

Editor-in-Chief: Alok Chandra Agrawal
Editorial Office Address: P-6, Doctors Colony, MCG Medical College, 481003 Jabalpur, India
Phone: 91-763-2672133
Email: drabhisagnawal@yahoo.co.in, drlokeagnawal@yahoo.co.in
Publisher: Dr Alok Chandra Agrawal

Language:
Abstracts: English
Full text: English

Index: Medical/Medicine: No
Current Contents: No



TM

**INDEX
COPERNICUS
INTERNATIONAL
2010**

JOURNALS MASTER LIST

ISI Patent Pending

1813 IND **Journal of Orthopaedics, The**

pISSN: 0975-7333

ICV: 2.98

Editor-in-Chief: Alok Chandra Agrawal
Editorial Office Address: P-6, Doctors Colony, MCG Medical College, 481003 Jabalpur, India
Phone: 91-763-2672133
Email: drabhisagnawal@yahoo.co.in
Publisher: Alok Chandra Agrawal

Language:
Abstracts: English
Full text: English
Frequency: 1 (twice) per year

Index: Medical/Medicine: No
Current Contents: No